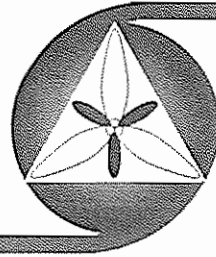


# Nowicky Pharma

Dipl.-Ing. DDr. Dr.h.c. W. Nowicky



Margaretenstraße 7  
A-1040 Vienna, Austria  
tel.: + 43-1-586 12 24  
fax: + 43-1-586 89 94  
nowicky@ukrin.com

## UKRAIN<sup>®</sup>

**Case reports by doctors  
from**

**Germany**

**USA**

**Portugal**

**Italy**

**Sweden**

**Poland**

**Lithuania**

**Switzerland**

**Belarus**

**United Kingdom**

**Russia**


**Ukraine**

**Georgia**

**Austria**

**Australia**

# Zentrum für onkologische, endokrinologische und minimalinvasive Chirurgie



To the  
Ministry of Health  
Abu Dhabi  
UAE

▪ Gemeinschaftspraxis  
Priv. Doz. Dr. med.  
Frank Gansauge  
Priv. Doz. Dr. med.  
Bertram Poch  
Priv. Doz. Dr. med.  
Michael Schwarz

▪ Privatpraxis  
Prof. em. Dr. med.  
Hans G. Beger

20-11-2006

## Re.: Ukrain in pancreatic cancer patients

Dear Sir,

During the past 7 years we have intensively investigated Ukrain in pancreatic cancer patients. Two studies were performed:

1. Ukrain in the palliative treatment of advanced pancreatic cancer. In this randomized study three treatment arms were compared. Gemcitabine-monotherapy (30 patients), Ukrain monotherapy (30 patients) and the combined treatment of Gemcitabine with Ukrain (30 patients). In both treatment protocols containing Ukrain the median survival times were significantly higher than in the Gemcitabine monotherapy arm. Ukrain was well tolerated.
2. Ukrain in the adjuvant treatment in pancreatic cancer. In this study 30 patients received Gemcitabine-Ukrain-combined therapy following resection for pancreatic cancer. The relapse free survival time was 21,7 months, the median survival time was 33,8 months which is much higher than survival times observed in protocols using adjuvant Gemcitabine monotherapy.

In my opinion Ukrain is a safe drug and significantly prolongs survival in the treatment of pancreatic cancer.

Due to these results registration of Ukrain is recommended.

With best regards

Frank Gansauge MD, PhD

▪ Donauklinik  
Abt. Visceralchirurgie  
Krankenhausstraße 11  
D-89231 Neu-Ulm  
Tel-Zentrale: +49 (0) 731 80 40  
clin@eurosurgery.de

▪ Illertalklinik  
Abt. Visceralchirurgie  
Krankenhausstraße 7  
D-89257 Illertissen  
Tel.: +49 (0) 7303 177 3700  
Fax: +49 (0) 7303 177 3709

▪ Praxis  
Süßerstraße 36  
D-89231 Neu-Ulm  
Tel.: +49 (0) 731 715 76 0  
Fax: +49 (0) 731 715 76 250  
info@eurosurgery.de

▪ Praxisgemeinschaft  
und  
Gemeinschaftspraxis  
KV Nr.: 70/97602

**Dr. T.R.Shantha, MD, PhD, F.A.C.A, D.A.B.A**  
Medical Director

**INTEGRATED MEDICAL SPECIALISTS, LLC.**

**Integrated Chemotherapy Specialists, LLC.**

115 Bayberry Hills, McDonough, Georgia, 30253 (Atlanta suburb)

Phone: 770-507-6564, Fax: 770-507-8266 Cell: 678-640-7705

[www.IPTMD.com](http://www.IPTMD.com), [WWW.Lymelink.com](http://WWW.Lymelink.com), Email: [Shantha35@aol.com](mailto:Shantha35@aol.com)

An Island of Hope in a Sea of Hopelessness, Healing is what we do for Life

Tuesday, November 28, 2006

To: The Ministry of Health

Abu Dhabi; UAE

**Dear Sir:**

The philosophy of our cancer center in the treatments of pancreatic and other cancers is based on our own research work, our experience, the work of various traditional cancer experts and alternative complementary therapists in US and around the world. It is not based on one person's work or one therapy or anecdotal experience. We select and study the therapies available all over the world, and use those which have the greatest benefit with least toxicity to the patients, based on the art and science of healing.

Coming back to the subject of pancreatic cancer; we have treated more than 100 cancers besides other cancers. The American Cancer Society predicts that, in 2006, about 33,730 people in the United States will be found to have pancreatic cancer and about 32,300 will die of the disease. That tells us that pancreatic cancer is fatal and only 3% of the people live more than 5 years after diagnosis and there is no silver bullet in horizon to cure the disease. Traditionally, most of the pancreatic cancers are treated using Gemcitabine (Gemzar- important mono chemotherapy) with or without 5-Fluorouracil (5-FU) and Capecitabine. These traditional therapies have severe life threatening side effects and can be deadly.

Based on the toxic horrendous side effects high dose chemotherapy, we started using Ukrain in combination of low dose selected chemotherapy (Gemcitabine) agent or Ukrain as single agent. The Ukrain was God sent. As single agent alone or along with low dose chemotherapy, many advanced pancreatic cancer patients who were sent home to die or hospice (less than a month life left) lived longer and some of them up to 3 years without toxic adverse life threatening side effects of high dose chemotherapy. These patients after starting treatment with Ukrain had less pain, jaundice was gone, tumor mass shrunk, appetite improved, and the patients gained weight with good quality life.


As for we know, Ukrain is a life saver and with or without small dose chemotherapy, and is the most effective therapy available for this deadly pancreatic cancer and for other type's cancers as well. Due to these findings, I highly recommend the registration and approval of non toxic Ukrain in UAE for its use in The Middle East and other nations around the World to treat pancreatic and other cancer patients; it is a life saving, life prolonging God sent remedy.

With best regards

Sincerely



T.R.Shantha, MD, PhD, F.A.C.A, D.A.B.A



## LAKE SIDE GARDEN MEDICAL CENTER

**John v. Limburg Stirum MD.**  
General Medicine FMH  
Neural Therapie SANTH

Seestrasse 155  
CH-8802 Kilchberg  
Tel.: ++41-(0)44-716 48 48  
Fax: ++41-(0)44-716 48 47

[www.praxis-seegarten.ch](http://www.praxis-seegarten.ch)  
[praxis@praxis-seegarten.ch](mailto:praxis@praxis-seegarten.ch)

Ministry of Health  
Abu Dhabi  
UAE

Kilchberg / Zurich, Nov 27, 2006

### **To whom it may concerne**

The medicine Ukrain has been used in our clinic since 1997. To date 44 patients have been treated having used nearly 1000 ampules.

Ukrain has been successful used in adjuvant treatment of cancer patients, mostly for metastases and recurrence prevention. The most common cancers have been colon, breast, prostate and pancreatic carcinomas.

I have to note an excellent toxicity profile of Ukrain. All cancer patients including advanced stage patients tolerated the treatment very well.

Sincerely

Dr. John van Limburg Stirum

Ministry of Education  
Republic of Belarus



Institution of Education  
"Yanka Kupala  
State University  
of Grodno"

LABORATORY OF BIOCHEMISTRY  
OF BIOLOGICALLY ACTIVE SUBSTANCES

52, BLK , Grodno, 230017 Belarus  
tel./fax: +375 (152) 48 68 10  
www. nil.grsu.by  
E-mail: lnefyodov@grsu.by

21.12.2006

THE MINISTRY OF HEALTH  
ABU DHABI  
U A E

Dear Sir,

NSC -631570 (Ukrain<sup>®</sup>) has been studied of the Institute of Biochemistry, Belarusian Academy of Science, Grodno State Hospital and at the Laboratory of Biochemistry of Grodno State University, Belarus, from 1994 until now.

In preclinical studies Ukrain<sup>®</sup> was proven to be safe and highly effective, inhibiting protein synthesis in cancer cells, selectively accumulating in cancer tissue and controlling cancer-induced metabolic imbalance. This drug inhibits metabolic processes in the tumor and causes metabolic disorders in cancer cells. Moreover, Ukrain<sup>®</sup> induced the changes in certain amino acids concentrations in biological fluids and tumor tissue in cancer patients. This would provide the background for application of Ukrain<sup>®</sup> together with monitoring of the changes in the content of amino acids and relative compounds for cancer detection.

Behind the creation of the new generation nontoxic, high specific antitumoral and immunomodulatory drug Ukrain<sup>®</sup>, which the confirmed effectiveness by the 4 000 of patients with different stages and localization of cancerous (mammary gland, urinary bladder, prostate and etc). It is the first anti-cancer drug to accumulate selectively in malignant cells (in both primary tumor and metastases) without affecting healthy cells.

Thus Ukrain<sup>®</sup> is the first malignocytolytic anticancer drug that is both highly effective and non-toxic in therapeutic dosage, with immune modulating, anti-angiogenic and antiviral effects.

Head  
Laboratory of Biochemistry  
of Biologically Active Substances  
Professor, PhD, M.D., D.h.c.,  
Honorary Academician of the Rome Academy  
"Guglielmo Marconi",  
Doctor of Science (Honoris Causa)  
of the Munchen University,  
Honorary Member of Belgian Order of Merit,  
A. Schweitzer Prize Winner

Leonid I. Nefyodov

Laboratory of Biochemistry of Biologically Active Substances  
52, BLK, Grodno, 230017, Belarus  
Tel/fax:+375 (152) 48 68 10; www.nil.grsu.by; E-mail: lnefyodov@grsu.by

**ФЕДЕРАЛЬНОЕ АГЕНТСТВО ПО ЗДРАВООХРАНЕНИЮ И СОЦИАЛЬНОМУ РАЗВИТИЮ**  
Государственное образовательное учреждение высшего профессионального образования  
**«САНКТ-ПЕТЕРБУРГСКАЯ ГОСУДАРСТВЕННАЯ МЕДИЦИНСКАЯ  
АКАДЕМИЯ ИМ. И.И. МЕЧНИКОВА ФЕДЕРАЛЬНОГО АГЕНТСТВА  
ПО ЗДРАВООХРАНЕНИЮ И СОЦИАЛЬНОМУ РАЗВИТИЮ»**  
ГОУВПО СПбГМА им. И.И. Мечникова Росздрава

195067, Санкт-Петербург,  
К-67, Пискаревский пр., 47

Тел. (812)543-96-09, факс: (812)740-15-24  
Эл. Почта: mechnik@gmail.com  
www.mechnik.spb.ru  
ОКПО: 01963172 ОКОНХ: 92110

№ \_\_\_\_\_  
на № \_\_\_\_\_ от \_\_\_\_\_

To the Ministry of Health  
ABU Dhabi  
UAE

April, 4, 2007  
St. Petersburg, Russia

Ukrain (NSC-631570) has been used in Russia at the St. Petersburg Medical Academy of Post-graduate Studies, Research Institute of Influenza, Research Institute of Military Medicine since 1993 and at the Department of Infections Diseases, State Mechnikov Medical Academy, St. Petersburg, Russia since 1999.


In preclinical studies the modulating effect of Ukrain on the blood erythrocytes antioxidant system (SH//SS ratio), antiviral properties at the experimental influenza virus infection and radiomodifying activity were revealed.

Clinical trials at the chronic hepatitis C patients shown high efficacy of Ukrain suggested by the disappearance of hepatitis C virus (HCV) in blood and normalization of hepatic function proofs (ALT, AST). Ukrain was effective even at the most unfavorable HCV genotype Tb. Treatment with Ukrain was especially effective if drug doses were selected individually for each patient based on the estimation of its influence on the blood thiol-disulfide (SH//SS) ratio. Treatment with Ukrain was without side effects.

Due to its immunomodulating, antioxidant, antiviral and radioprotective properties Ukrain is especially perspective to be used in rehabilitation after recovery from the different, including viral diseases, irradiation and in postoperative period for the increasing quality of life.

Head of Department of Infections Diseases Prof. T.V. Sologub, MD, PhD

Dr. I.V. Voltchek, MD





DIPARTIMENTO DI MORFOLOGIA UMANA  
UNIVERSITÀ DEGLI STUDI DI MILANO  
*Facoltà di Medicina e Chirurgia*  
DIPARTIMENTO DI MORFOLOGIA UMANA  
*Dr. Nicoletta Gagliano*

To the  
Ministry of Health  
Abu Dhabi  
UAE

Milan, 28 november 2006

Dear Sirs,

During the last 3 years we have intensively analyzed the effect of Ukrain in an in vitro experimental model.

In particular, in human cultured glioblastoma cells we analyzed cell proliferation, and the expression of gene and proteins involved in tumor invasion and apoptosis.

As a whole, our results suggest that Ukrain influences some major aspects of progression in human glioblastoma cells, such as cell proliferation, the expression of a pivotal protein in the mechanisms leading to tumor cell invasion and survival, and apoptosis. Our data suggest that Ukrain may have some potential for the therapy of brain tumors and could well also help extend our understanding of the mechanisms of this antitumor and chemopreventive potential.

Yours sincerely,

Nicoletta Gagliano, PhD

## Professor Serge Jurasunas

Integrative Medicine

Board Certificate Naturopathic Physician  
American Naturopathic Medical Certification  
and Accreditation Board inc. - N° 01117

Lisbon, the 20<sup>th</sup> December 2006

Nowicky Pharma  
Margaretenstrasse, 7  
1040 Vienna  
AUSTRIA

I am working with cancer for the past 30 years and know about Ukraine for over 20 years. Up my wide experience in treating cancer patients including advanced cases I can describe Ukraine as one of my most powerful anticancer drug with only low percentage of negative effects from symptoms but not toxic adverse effects.

Basiquely I have been used Ukraine when chemotherapy failed to bring results to patients, or during chemotherapy which apparently is less effective but even so increase the killing of cancer cells.

We have been used on bad advanced cases such liver, pancreas with metastasis diffusion and have obtain significative results from extermination of secondary tumors and decreasing antigene tumor markers with better quality of life and life extension.

Today standard therapy has failed to the expectation to cure of cancer with metastasis. Ovarian, melanoma, lung, colon cancer has a low five years survival rate not speaking of the strong adverse effects and deteriorating physical and psychological condition of patients.

What can be done to improve this situation and indeed to enhance the effectiveness of chemotherapy or substitute chemotherapy when it become intolerable or inefficient to cancer patients.

Many new safe natural compounds or phytochemicals are now experimented in USA under the guidance of the National Office and Alternative and Complementary Medicine and the National Institute because it is urgent to find some better approach to cancer.

The society of Integrative Oncology (USA) of which I am member with active participation is also working into this direction with the objective to teach Oncologist some integrative approach.

Therefore Ukraine should be seen of great support and as I new conception to improve the treatment of cancer patients

Dr. Serge Jurasunas

Member of the Society of Integrative Oncology (USA)



**Dr Mikael Nordfors**  
**Kunlabori Health**  
Reutersgatan 2 B  
413 20 Göteborg, Sweden  
Ph +46 31 203730  
mikael@kunlabori.org


November 29, 2006

**To whom it concerns**

My name is Mikael Nordfors, and I am a medical doctor and author from the country of Sweden. I have with interest noted Dr.Wassil Nowicky's amazing discoveries regarding the cancer medication Ukrain, and also with great despair and sorrow noted his problems getting this potentially revolutionizing and life-saving medication registered in Europe and USA.

Therefore I am currently in the process of nominating him for the right Livelihood award, also called the Alternate Nobel Price. I will also include a chapter about him and Ukrain in my new book, "Totalitarian medicine, the No 1 killer in the Western World"?

Sincerely,

A handwritten signature in black ink, appearing to read 'Mikael Nordfors', written in a cursive style.

Mikael Nordfors

MD and co-author of the International Bestseller "Hypericum & Depression".

Aleksejus Mickonas, MD, PhD  
Oncology Institute of Vilnius University  
ENT, Head and Neck Surgery Division  
LT-06203 Vilnius  
LITHUANIA  
E-mail: [mickonas@yahoo.com](mailto:mickonas@yahoo.com)

January 22, 2007

To:  
The Ministry of Health  
Abu Dhabi  
UAE

Dear Sir,

I have been working with cancer for the past 15 years. I first heard about Ukrain over one year ago, as my mother was treated for lymphoma (I st). Ukrain was successfully used in the adjuvant therapy of my mother.

Today I have more expository cases of successful cancer treatment. After starting treatment with Ukrain the patients had less pain, decreased discomfort and Ukrain was very well tolerated and therefore improved the quality of life of the patients during and after treatment.

In my wide experience in treating cancer patients with Helixor (mistletoe therapy) I can confirm that Ukrain is the drug with the most powerful anticancer activity. I hope that Ukrain as well as Helixor will be registered in the European Union.

The pre-operative administration of Ukrain leads to tumor encapsulation and therefore significantly improves operability. I would like to present for your attention a case report of the treatment of a woman with advanced cancer of the tongue (T3N0M0).

#### TREATMENT OF TONGUE CANCER WITH NSC 631570 (UKRAIN): CASE REPORT

**Background.** Cancer of the oral tongue is the most common site for oral cavity cancer, accounting for 20-50% of all cancers of the oral cavity. Seventy-five percent of these cancers occur in the oral tongue. Over 6,000 new diagnoses and nearly 2,000 deaths occur each year as a result of this cancer. RT may be curative in early cancer (T1-2). It preserves normal anatomy and tongue function. Non-advanced tongue cancer is also treated with partial glossectomy. For patients with advanced disease (>4 cm) combined treatment with surgery and RT is necessary. However, anatomy and function of the tongue are so complex that restoring its functionality after extirpative procedures has proved very difficult. Patients with advanced cancer usually require radical surgery resulting in severe alteration in speech and swallowing.

#### Case report

A 48 year-old woman presented with a 6-month history of progressive canker, pain and discomfort in the tongue. She arrived at the Oncology Institute of Vilnius University on 24<sup>th</sup> August 2006. She worked as a bank clerk - talking a lot on the phone was her daily routine. She had never smoked and was not on medication. A review of the cytological investigation at Orthodontic Clinic on 20<sup>th</sup> March 2006 showed that the patient had squamous cell carcinoma; however the patient refused the treatment. The tumor infiltrated the middle third of the right side of the tongue, more than 4 cm in size without obvious boundaries, with a deep irregular ulceration approximately 3x1 cm in size. Biopsy was performed. Tumor biopsy showed poorly differentiated squamous cell carcinoma (G3) represented by the spread of polygonal pleomorphic tumor cell groups in desmoplastic stroma. Head and neck ultrasound and computer tomography (CT) imaging revealed no metastases. Concilium suggested concomitant chemoradiotherapy treatment which the patient refused. Resection of the half of the tongue was not acceptable for the patient because of speech disorder and her fear of losing her job.

Since October 2006 she has been treated with NSC 631570. No other medications were used. Two weeks after the start of the therapy the tumor border became more obvious visually and palpatory. The inner border of the tumor was 0.5 cm from middle line of the tongue. The patient reported a general improvement. The patient consumed 400 mg of the drug before the surgery. The tumor was located on the middle third of the right side of the tongue, 3x4 cm in size with a 2x1 cm irregular size deep canker. Ultrasonography and CT control did not reveal distant metastases. Organ-saving surgery was suggested and agreed by the patient. On November 14, 2006 the tumor was removed within the healthy tissue. The postoperative course was not complicated. The wound healed quickly. The patient further received NSC 631570 twice a week according to the schedule 5 + 20 mg for two months after


surgery.

**Results.** Pathological examination revealed a large 2.5 cm diameter encapsulated mass of the tongue is present and shows central ulceration. Microscopically the tumor is moderately differentiated squamous cell carcinoma originating from the superficial squamous epithelium (2x) and infiltrating striated muscle of the tongue (2x(2)). A moderate amount of extracellular keratinization is present (40x). Intratumoral mononuclear inflammatory cell response is scant. Tumor also shows a focal moderate desmoplastic stromal reaction (10x(2)). Speech and swallowing function did not suffer after the surgery. After 1 and 2 months of follow-ups, the patient remained free of disease, and ultrasound control was normal without residual tumor. All clinical and laboratory parameters were within reference range. Her overall condition is excellent.

**Conclusion.** Treating with NSC 631570 the tumor gradually decreased and the tumor border became more obvious, therefore organ-saving surgery was possible to perform with high functional results. Treatment with NSC 631570 was used instead of resection of half of the tongue and aggressive chemoradiotherapy treatment which seemed to be optimal in this case. NSC 631570 decreased discomfort and pain and therefore improved the quality of life of the patient during and after the treatment. Speech and swallowing function did not suffer and did not influence the career of the patient. The tumor resection specimen showed a higher degree of lymphoid infiltration and fibrosis compared to the presurgical biopsy, possibly reflecting an enhanced immune response of the patient.

This paper will be presented on June 30th - July 4th, 2007 at the 6th European Congress of Head and Neck Surgery in Vienna.

Sincerely

A handwritten signature in black ink, consisting of a large, stylized loop followed by a horizontal line and a shorter vertical stroke.

A. Mickonas MD, PhD



MEDICAL UNIVERSITY OF LUBLIN  
DEPARTMENT OF TOXICOLOGY

8 Chodźki Str., 20-093 Lublin,  
tel./fax +48 81 740-58-80

---

### Ukrain: Statement and Recommendation (25 January 2007)

I began studying the drug Ukrain (NSC – 631570) thirty years ago: originally at the Lublin Medical Academy Department of Pharmacology and then from 1999 my team and I have been working on it at the Medical University Department of Toxicology. After screening studies it was noted that the drug Ukrain was very well tolerated in mice and rats (after intraperitoneal injection, ip). After ip administration in large doses Ukrain shows depressive effects on the central nervous system in rodents. Ukrain shows no neurotoxic effects and does not cumulate. A very strong analgesic effect of Ukrain in rodents is indicated. However, administered in combination with morphine, Ukrain antagonises the analgesic effect.

After ip treatment with Ukrain (single dose, 10-day, 3-month and 6-month periods) practically no changes were observed in haematological or biochemical parameters in mice and rats. Our research showed that 6-month treatment with Ukrain normalises biochemical and biomechanical parameters and decreases ovariectomy-induced osteoporosis in rats. Current studies have shown that Ukrain diminishes the toxic effects of alcohol as well as the actions of some heavy metals in rats.

Ukrain also has immunocorrective properties and in my opinion deserves further studies. Studies concerning the interaction of Ukrain with other simultaneously administered drugs during one treatment are especially crucial.

*Wójtowicz Ewa*

Prof. dr hab. Ewa Jagiełło-Wójtowicz



**The Dove Clinic for Integrated Medicine**

Medical director Dr Julian Kenyon MD MB ChB  
Dr Tracey Covell BM DRCOG DSSP MRCGP

Ref: JK/vh/jk0128

12 May 2003

**FAXED**  
12.5.03

Dr Wassil Nowicky  
Nowicky Pharma  
MargaretenstraBe 7  
A-1040 Vienna  
Austria

cc  
Fax No. 43 1 586 8994

Dear Dr Nowicky

Regarding your lawyer talking with the Medicines Control Agency in London for obtaining 'orphan' drug status for Ukrain.

We have a great deal of experience with Ukrain and a whole range of solid cancers. We use tumour marker Pyruvate Kinase which we find very reliable for a whole range of solid cancers (we can supply references), and we consistently find that following a course of Ukrain the tumour markers drop over 90% of the time.

We have had 4 cases of pancreatic cancer, treated using Ukrain as according to the 2 papers on Ukrain, The Treatment of Pancreatic Cancer (figurative Ukrain for the treatment for pancreatic cancer Zemskov et al 19 June 2002, Springer-Verlag 2002, NSC-63157 (Ukrain) and Palliative Treatments of Pancreatic Cancer, the results of Phase 2 trial. Gansauge et al 13 February 2002 Springer-Verlag 2002). All of these patients were in Stage 4 pancreatic cancer, with an outlook of approximately 2 months. All have lived beyond 9 months.

We find that Ukrain is extremely well tolerated, and to that end, is most useful in patients who have had repeated conventional chemotherapy regimes, and are no longer able to tolerate any further standard conventional chemotherapy.

We hope this evidence will be of some help to you, in settling the issue with the MCA

Yours sincerely

Dr Julian Kenyon

Hockley Mill Stables Church Lane Twyford near Winchester Hampshire SO21 1NT UK  
Telephone 01962 718000 Fax 01962 718011 www.doveclinic.com  
also at: Northfields Farm Hazeley Road Twyford near Winchester Hampshire SO21 1QA UK  
Telephone 01962 717800 Fax 01962 717801

97 Harley Street London W1G 6AG Telephone 020 7486 5588 Fax 020 7487 4442  
The Dove Clinic Limited Registered in England 3927313

JNK/elh/jk3177

7 January 2003

Dr Rashid M. Aba Al-Kheil/Director General  
Sultan Bin Abdulaziz Humanitarian City  
PO Box 54399  
Riyadh 11536  
Saudi Arabia

AIR MAIL

Fax No. 00966 1562 0166

Dear Dr Aba Al-Kheil

*I've been asked to write to you by Dr Nowicky of Nowicky Pharma, regarding the use of Ukrain. We use Ukrain in a whole range of solid tumours. For example we've had significant clinical results in breast, colon, lung and ovarian cancer, as well as pancreatic cancer. There are many, many papers published on the use of Ukrain and you can see some of those references on our website ([www.doveclinic.com](http://www.doveclinic.com)). We also have other novel cytotoxic treatments that do not carry the downsides of chemotherapy, and I'm happy to pass information on about these treatments as well, if you are interested.*

*Ukrain is very well tolerated.*

*Yours sincerely*

Dr J N Kenyon

A.A.Bogomolet's NATIONAL MEDICAL UNIVERSITY  
DEPARTMENT of GENERAL SURGERY

03039 Ukraine, Kyiv-039, prosp.Golosyivskiy 59-b (0038044-263-4252, 26532690

№ 01/01

08.01.2003.

Dr.Rashid M.Aba Al-Kheil  
Director General  
Sultan Bin Abdulaziz Humanitarian City

Ukrain (NSC-631570) has been used at the Department of General Surgery, National Medical University, Kyiv, Ukraine and the Kyiv Hospital of Liver, Pancreas and Bile Ducts Surgery from 1994 until now with promising results. We have performed clinical studies with patients with colorectal and pancreatic carcinoma and treated patients with liver, gall-bladder, gastric and breast cancer, cervical and ovarian cancer, renal and prostate carcinoma. For example, in a randomised study with colorectal carcinoma the survival rate (up to 21 months) in the Ukrain-treated patients was 78.6% and 33.3% in a group treated with 5-fluorouracil.

Remissions after treatment with Ukrain were achieved even in cases of advanced metastatic cancer; the best success rate with Ukrain was achieved with cancer patients starting treatment at the earliest stage of disease. From a surgical point of view preoperative administration of Ukrain (minimum 2 weeks before surgery) often facilitates resection of the tumor inducing the development of "capsula" around the tumor. Postoperative treatment by Ukrain improves wound healing, rehabilitation of the patients and prevents keloid development. In clear contrast to all available chemotherapeutic compounds, Ukrain combines very low toxicity with high therapeutic efficacy. Patients treated with Ukrain in doses between 5 and 50 mg per application were observed for up to 7 years without any evidence of toxic or cumulative effect.

In 2002 we published results of Ukrain treatment of patients with advanced pancreatic cancer. One-year survival was 76% in the Ukrain group, compared to 9.5% in the control group. In the study by Burris et al. of one hundred and twenty-six patients treated with gemcitabine (which is now standard therapy in advanced pancreatic cancer) there were no survivors beyond 19 months, whereas in our study 36-month survival was 23.8% after Ukrain therapy.

We have also interesting unpublished data on the effectiveness of intraarterial administration of Ukrain in the treatment of liver metastases of different primary malignant tumours. On the basis of wide experience of using Ukrain in patients with various malignant diseases we have worked out original schedules of Ukrain therapy that could be recommended for use in clinical practice in pre-, intra- and postoperative periods aiming for an improvement in the quality of life, maximal survival and inhibition of metastases development.

Head of General Surgery Department

PD. Dr. Y. M. Susak





Georgian Academy of Sciences  
INSTITUTE OF RADIOLOGY AND INTERVENTIONAL  
DIAGNOSTICS

№ 18/09

" 8 " 01 - 2003

To: Dr. Rashid M. AbaAl-Kheil  
Director general  
Sultan Bin Abdulaziz Humanitarian City  
P.O. Box 54399  
Riyadh 11536  
Saudi Arabia  
Fax: + 966 1 562 0166

NSC-631570 (Ukrain) has been used in Georgia since 1996. On the basis of it's good toxicity profile and high efficacy it was approved for clinical use by Ministry of Health Care (Certificate No. 002861).

Treatment with Ukrain causes clinical remission of different oncological diseases in 30-45 % of cases. The best results have been achieved in the treatment of oncohematological patients. Ukrain results in fast postoperative healing and rehabilitation, also restoration and improvement of the immune system.

Sincerely Yours,

Prof. F.Todua  
Director of the Institute  
Head Radiologist of Georgia,  
President of Association of Georgian Radiologists

Тбилиси - 380012, ул. Теодоре Мгвделли 13 Грузия  
13, Tevdore Mgvdeli str., Tbilisi-380012, Georgia

☎ 94-02-89,  
Fax: (995 32) 34-49-23  
Email: radiag@access.sanet.ge





POS

PRIVATKLINIK  
**VILLA MEDICA®**  
ZENTRUM FÜR GANZHEITLICHE MEDIZIN

Privatklinik Villa Medica Dr. Aschhoff Postfach 47 67476 Edenkoben/Weinstraße

Firma  
Nowicky Pharma  
Herrn Dr. W. Nowicky  
Margaretenstrasse 7

Edenkoben den 13.05.2003

A-1040 Wien

Sehr geehrter Herr Dr. Nowicky,  
sehr geehrte Damen und Herren

wie Ihnen bekannt ist, wende ich Ihr Präparat Ukrain® seit September 1997 bei den unterschiedlichsten malignen Tumorerkrankungen an

Zwischen September 1997 und Januar 2003 habe ich das Präparat Ukrain® bei 47 verschiedenen malignen Tumorarten angewandt und insgesamt 437 Patienten damit behandelt

Zu den behandelten malignen Tumoren gehörte auch das Pankreas-Karzinom. Behandelt wurden bisher 28 Patienten mit inoperablen Pankreas-Karzinomen bzw. Patienten, die auf die Standard-Therapien mit Gemcitabine oder 5-Fluoruracil nicht oder nicht mehr ansprachen. Bei diesen Patienten konnten wir in 24 Fällen (85,7%) noch eine Partialremission erreichen. Lediglich bei 4 Patienten (14,3%) war der Progress nicht zu beeinflussen.

Von den behandelten Patienten kamen 5 Patienten direkt nach Diagnostik und/oder Operation primär in unsere Behandlung. 23 Patienten kamen nach einer ergebnislosen Therapie mit anderen Chemotherapeutika (Gemcitabine, 5-FU o.a.) in unsere Behandlung

Hierbei gestaltete sich das Therapieprotokoll wie folgt: Es wurden jeden 2. Tag 0,3 mg/kg KG Ukrain® in 250ml 5% Glucose langsam infundiert über einen Zeitraum von 3 Wochen. Danach erfolgte die Therapie 1-mal pro Woche fortlaufend

Nebenwirkungen traten während der gesamten Therapiezeit nicht auf

Vom Beginn der Behandlung der Patienten mit einem Pankreas-Karzinom mit Ukrain® - und zumeist nicht vom Erkrankungsbeginn - konnten wir noch Überlebenszeiten zwischen 6 Monaten und 36 Monaten erzielen

Bei den klinischen Behandlungen der Patienten und den dazu notwendigen objektiven Kontrollen sind über den gesamten Zeitraum von September 1997 bis Januar 2003 keine Unterschiede in der Wirkungsweise des Präparates Ukrain® aufgefallen

Mit freundlichen Grüßen  
PRIVATKLINIK VILLA MEDICA

  
Dr. med. Burkhard Aschhoff  
Chefarzt, Klinikleitung

## Tumor-Arten

	Tumor	Total	VR		PR		Progress	
			Zahl	%	Zahl	%	Zahl	%
1.	Prostata-Ca	74	54	73	16	22	4	5
2.	Mamma-Ca	61	19	31	26	43	16	26
3.	Colon-Rektrum-Ca	48	8	16,7	31	64,6	9	17,7
4.	Pankreas-Ca	28			24	85,7	4	14,3
5.	Bronchial-Ca, Adeno	26	2	7,7	19	73,1	5	19,2
6.	Bronchial-Ca, kleinzellig	24	5	21	15	62,5	4	16,5
7.	Ovarial-Ca	18	6	33,3	8	44,4	4	22,3
8.	Magen-Ca	16	2	12,5	12	76	2	12,5
9.	Siegelring-Ca	12			8	66,6	4	33,3
10.	Plattenepithel-Ca	12			10	83,3	2	16,6
11.	Malignes Melanom	12			10	83,3	2	16,7
12.	Ewing-Sarkom	8	4	50	4	50		
13.	Vulva- + Cervix-Ca	8			8	100		
14.	Nierenzell-Ca	8			6	75	2	25
15.	Oestogenes Sarkom	7			5	71,5	2	28,5
16.	Astrozytom	6	4	66,6	1	16,6	1	16,6
17.	Gallenblasen-Ca	6			6	100		
18.	Hepatozelluläres Ca	6			4	66,6	2	33,3
19.	Neuroblastom	5	3	60	1	20	1	20
20.	Seminom	4	3	75	1	25		
21.	Wilmstumor	4			1	25	3	75
22.	Glioblastom	4			3	75	1	25
23.	Blasen-Ca	4	2	50	1	25	1	25
24.	Karzinome unkl. Genese	3	1	33,3	2	66,6		
25.	Rhabdomyosarkom	3			1	33,3	2	66,6
26.	Medulloblastom	3			2	66,6	1	33,3
27.	Non-Hodkin-Lymphom	3			2	66,6	1	33,3
28.	Plasmocytom	2	1	50			1	50
29.	Pleuramesotheliom	2			2	100		
30.	Appendix-Ca	2			2	100		
31.	Mesotheliom	2			1	50	1	50
32.	Weichteiltumor unbk.	2			1	50	1	50
33.	Klutskin-Tumor	2			1	50	1	50
34.	Epidermoid Bronchial-Ca	1			1			
35.	Lymphoepith. Nasoph. Ca	1			1			
36.	Nephroblastom	1					1	
37.	Leydig-Zell-Tu	1					1	
38.	Leyomyosarkom	1					1	
39.	Neuroektodermaler Tu	1					1	
40.	Histiozytom	1					1	
41.	Mukoepidermoides-Ca	1					1	
42.	Peritonelaer Weichteil-Tu	1					1	
43.	Schwannom	1					1	
44.	Ependymom	1					1	
45.	Neuroektodermaler-Tu	1					1	
	<b>Ergebnis</b>	<b>437</b>	<b>114</b>	<b>26,1</b>	<b>236</b>	<b>54</b>	<b>87</b>	<b>19,9</b>

**Dr. med. Ralf Kleef**

Allgemeinmedizin

Naturheilverfahren

Institut für Wärme- und Immuntherapie (IWIT)

Windmühlgasse 30/7



Windmühlgasse 30 / 7

A – 1060 Wien

Tel: + 43(1) 585 73 11

Fax: + 43 (1) 585 73 11 – 20

office@hyperthermie.at

---

Allg. beeideter u. gerichtlich zertifizierter Sachverständiger f. Hyperthermie u. Komplementärmedizin

**Ministry of Health**

**Abu Dhabi**

**UAE**

Friday, November 22nd, 2006

To whom it may concern

IWIT is the leading Institute for Hyperthermia in Austria. A prime focus of our clinical work is the treatment of cancer patient. An important part of our treatment regime in many patients is the treatment with the anti-cancer agent Chelodonium Majus derivate UKRAIN®.

This is to certify, that our outpatient department has used this successful immunotherapy in a wide a variety of cancer patients including cancer of the colon, brain, lungs, sarcoma, skin and bones.

Notably, an excellent side effect free application was observed. No patient reported side effects and in some cases remarkable longstanding remissions could be observed. Two of such case reports are enclosed.

Dr. med. Ralf Kleef, MD

Chief, Institute for Heat and Immunotherapy, IWIT, Vienna, Austria

Enclosure



---

Institut für Wärme- und Immuntherapie (IWIT)

[www.hyperthermie.at](http://www.hyperthermie.at)

## National Cancer Institute's Best Case Series Program in Alternative Medicine

### Case Report Format: Solid Tumors

Following is a sample case report format that you may use to submit each of your Best Case Series Case Reports regarding an alternative therapy for solid tumors. If you would like an electronic version of this form, contact the OCCAM. You may use a different format for your case reports if you wish, but all of the applicable data listed below must be included.

Patient Name:           W.W.          

Diagnosis:           Renal Cell Cancer, Liver Metastasis, Abdominal wall metastasis          

#### 1. Clinical history

a. Date of birth 04.07.1925 or age 76 at presentation to your office

b. Sex           Male

c. Date of diagnosis of initial tumor   February 1991

Operated by Prof Meier, Dep. Urology, University of Vienna

How documented?

1. Histology report from 25<sup>th</sup> February 1991 following resection of left kidney:  
**Solid, partially tubular clear cell Renal Cell Carcinoma, pT3a, pN0, Mx, G2**

2. Histology report from 2<sup>nd</sup> March 1995 following liver metastasis:  
**Metastasis of a clear cell Renal Cell Carcinoma**

3. Histology report from 8<sup>th</sup> March 1995 following liver metastasis:  
**Metastasis of a clear cell Renal Cell Carcinoma**

4. Histology report from 22<sup>nd</sup> July 1997 following liver metastasis:  
**Skin Metastasis of a clear cell Renal Cell Carcinoma**

5. Histology report from 14<sup>th</sup> October 1997 following liver metastasis:  
**Metastasis of a clear cell Renal Cell Carcinoma**

6. Histology report from 15<sup>th</sup> October 1997 following liver metastasis:  
**Metastasis of a clear cell Renal Cell Carcinoma**

7. Histology report from 16 June 1999 following liver metastasis:  
**Metastasis of a clear cell Renal Cell Carcinoma**

- d. History of illness with dates of onset of all disease-related symptoms – Please complete Table 1d.

Table 1d. History of Illness

Disease-related symptoms	Date of onset	Treatment	Response
Macrohaematuria	2/1991	Nephrectomy left kidney	CR
1 <sup>st</sup> Liver metastasis	9/1995	Abdominal Resection of one 4cm tumor left liver lobe	PD
2 <sup>nd</sup> Liver metastasis	6/1996	Abdominal Resection of one 6cm tumor left liver lobe	PD
Abdominal wall metastasis Resection of tumor in Abdominal wall 1st Chemotherapy: Interferon s.c. over 1 year (no dosage known)	University of Vienna (AKH)	10/1996	PD
3rd Liver metastasis Abdominal Resection of tumor left liver lobe and resection of gall bladder	University of Vienna (AKH)	02.10.1997	PD
4th Liver metastasis Abdominal Resection of tumor left liver 2nd Chemotherapy: (no drug and dosage known)	University of Vienna (AKH)	15.04.1998	PD
Discontinuation of chemotherapy due to PD	University of Vienna (AKH)	7/1998	PD

- e. History of prior cancer treatment (if any) – Please complete Table 1e. Provide as much information as possible.

Table 1e. Prior Therapies

Therapy	Practitioner's Name and Contact Information	Dates	Response
Nephrectomy left kidney	University of Vienna (AKH) Urology, Dep. Prof. Dr. Meier, Währinger Gürtel 18-20, A-1090 Vienna, Tel: +43 (1) 40400	February 1991	CR
1 <sup>st</sup> Liver metastasis Abdominal Resection of one 4cm tumor left liver lobe	University of Vienna (AKH) Prof. Dr. R. Steininger	9/1995	PD
2 <sup>nd</sup> Liver metastasis Abdominal Resection of tumor left liver lobe 1 <sup>st</sup> Chemotherapy: Interferon s.c. over 1 year until 6/1997	University of Vienna (AKH) Prof. Dr. R. Steininger	6/1996	PD
Abdominal wall metastasis Resection of tumor in Abdominal wall 1 <sup>st</sup> Chemotherapy: Interferon s.c. over 1 year	University of Vienna (AKH) Prof. Dr. R. Steininger	10/1996	PD
3 <sup>rd</sup> Liver metastasis Abdominal Resection of tumor left liver lobe and resection of gall bladder	University of Vienna (AKH) Prof. Dr. R. Steininger	02.10.1997	PD
4 <sup>th</sup> Liver metastasis Abdominal Resection of tumor left liver 2 <sup>nd</sup> Chemotherapy: (no drug and dosage known)	University of Vienna (AKH) Prof. Dr. R. Steininger	15.04.1998	PD
Discontinuation of chemotherapy due to PD		7/1998	PD

1 <sup>st</sup> local recurrence in the area of nephrectomy: 7cm tumor with infiltrating of aorta; resection non in sano, resection of left part of pancreas (see attached operation report)	University of Vienna (AKH)	06.06.1999	PD
Until June 2001 no further treatment CT Thorax & Abdomen: PD, one old liver metastasis is progressing to 4.3cm, 2 new lesions: 2.2 and 3.1cm (see attached CT report)	University of Vienna (AKH)	13.06.2001	PD
No further treatment offered due to PD	University of Vienna (AKH)	6/2001	PD
<u>Begin of CAM treatment</u>	Villa Medica Dr. Burkhard Aschhoff Klosterstraße 179, D-67476 Edenkoben/ Weinstr. FRG Tel: +49 (6323) 802 0 Fax: +49 (6323) 7943	20 <sup>th</sup> August 2001 until 9 <sup>th</sup> September 2001	SD
<u>Continuation of CAM treatment</u>	Dr. med. Ralf Kleef Windmühlgasse 30 / 7 / 2 A-1060 Wien Tel: +43 (1) 585-7311 Fax: +43 (1) 585-7311-20 Mobile:+43 (676) 421-3961 Email: kleef@hyperthermie.at <a href="http://www.hyperthermie.at">www.hyperthermie.at</a>	9 <sup>th</sup> September 2001 until today	SD

2. Disease Prior to CAM Therapy

- a. Results of physical examination just prior to initiation of CAM therapy – Please complete Table 2a.

Table 2a. Physical Examination

Detectable Cancer Sites	Measurement
Weak patient, inappetence weight loss to 62 kg Karnofsky index 60%	CT Thorax & Abdomen: PD, one old liver metastasis is progressing to 4.3cm, 2 new lesions: 2.2 and 3.1cm (see attached CT report from 13.06.2001)

Check that the following documents are attached to this Case Report:

Reports	Attached
b. Pathology report of primary tumor	
c. Pathology reports of recurrent or metastatic disease	
d. Imaging reports (x-ray, CT scans, bone scans, MRI) taken prior to initiation of CAM therapy	



### 3. Treatment Descriptions

- a. CAM treatment description – Please complete Table 3a. Provide as much information as possible.

Table 3a. CAM Treatment Descriptions

	Dates	Response
No further treatment offered CT Thorax & Abdomen: PD, one old liver metastasis is progressing to 4.3cm, 2 new lesions: 2.2 and 3.1cm (see attached CT report from 13.06.2001)	June 2003	PD CT scan (see Report from 13.06.2001)
20 <sup>th</sup> August 2001 <b>Begin of 1<sup>st</sup> local hyperthermia treatment</b> with radiofrequency 13,56 MHz, 100 W power for 50 Minutes, <u>3x/weekly</u> for 3 weeks until end of September 2001	20 <sup>th</sup> August 2001 until 9 <sup>th</sup> September 2001	SD CT scan (see Report from 14.09.2001)
<b>Combined with each local hyperthermia treatment intravenous administration of:</b> <b>20mg Ukraine (cheledonium majus, Thiohepa) in Glucose 5% 250ml, Vitamine C 10.000mg</b>	9 <sup>th</sup> September 2001 until today	
2 <sup>nd</sup> local hyperthermia treatment with radiofrequency 13,56 MHz to <u>3x/weekly</u> for 1 week until end of November 2003	11 <sup>th</sup> November 2001 until 17 November 2001	SD (clinical)
3 <sup>rd</sup> local hyperthermia treatment with radiofrequency 13,56 MHz to <u>3x/weekly</u> for 1 week until 23 December 2001	16 <sup>th</sup> December 2001 until 23 December 2001	PD CT scan (see Report from 01.02.2002)
4 <sup>th</sup> local hyperthermia treatment with radiofrequency 13,56 MHz to <u>3x/weekly</u> for 1 week until end of April 2003	7 <sup>th</sup> April 2002 until 14 <sup>th</sup> April 2002	PD CT scan (see report from 30.04.2002)
5 <sup>th</sup> local hyperthermia treatment with radiofrequency 13,56 MHz to <u>3x/weekly</u> for 1 week until end of April 2003	2 <sup>nd</sup> February 2003 until 9 <sup>th</sup> February 2003	SD CT scan (see report from 08.07.2002)
<b>Beginning at 9<sup>th</sup> September 2001 Infusion of:</b> <b>20mg Ukraine (cheledonium majus, Thiohepa) in</b>		SD CT scan (see

<p>Glucose 5% 250ml, Vitamine C 10.000mg, after this:          Infusion of Selenium 500ug i.v.          Rhythm: 3 Weeks therapy, 3 weeks rest, 3 weeks          Therapy until today</p>		<p>report from          02.10.2002)</p>
<p>Beginning at 9<sup>th</sup> September 2001 Infusion of:          20mg Ukraine (cheledonium majus, Thiohepa) in          Glucose 5% 250ml, Vitamine C 10.000mg, after this:          Infusion of Selenium 500ug i.v.          Rhythm: 3 Weeks therapy, 3 weeks rest, 3 weeks          Therapy until today</p>		<p>SD/PD          CT scan (see          report from          10.06.2003)</p>
<p>Beginning at 9<sup>th</sup> September 2001 Infusion of:          20mg Ukraine (cheledonium majus, Thiohepa) in          Glucose 5% 250ml, Vitamine C 10.000mg, after this:          Infusion of Selenium 500ug i.v.          Rhythm: 3 Weeks therapy, 3 weeks rest, 3 weeks          Therapy until today</p>		<p>SD          CT scan (see          report from          08.09.2003)          Patient fit &amp;          well,          Karnofsky          100%</p>

- b. Other concurrent interventions (if any) – Please complete Table 3b. Provide as much information as possible.

Table 3b. Concurrent Interventions

Therapy	Practitioner's Name and Contact Information	Dates
EMX since 6/2003 Consists of natural lactic acid- and photosynthesis bacteria and yeast. (Prof. Higa Japan)	<b>Dr. med. Ralf Kleef</b> Windmühlgasse 30 / 7 / 2 A-1060 Wien <b>Tel: +43 (1) 585-7311</b> <b>Fax: +43 (1) 585-7311-20</b> <b>Mobile:+43 (676) 421-3961</b> <b>Email:</b> <b>kleef@hyperthermie.at</b> <b><u>www.hyperthermie.at</u></b>	June 2003 until today

#### 4. Response to CAM Intervention

If available, please provide bidimensional tumor measurements (largest perpendicular diameters) of all known sites of disease and date of measurement. Completion of this portion of the form is optional but if the patient has had less than a complete remission this information will help in determining the magnitude and duration of the response to therapy.

Table 4a. Radiographic Follow-up

Detectable Cancer Site	Measurement	Date
<b>CT-Thorax Abdomen:</b> PD, one old liver metastasis is progressing to 4.3cm, 2 new lesions: 2.2 and 3.1cm	Liver metastases: 4.3cm 2.2cm 3.1cm	Response PD CT scan (see Report from 13.06.2001)
<b>Begin of CAM Treatment</b>		
CT- Thorax-Abdomen: SD of liver metastasis	Liver metastases: 5x4cm 2cm 2cm	SD CT scan ( see report from 14.09.2001)
CT- Thorax-Abdomen: PD of liver metastasis	Liver metastases: 5.5cm 3cm 2cm New: 1cm in segment 8	PD CT scan (see Report from 01.02.2002)
CT- Thorax-Abdomen: PD of liver metastasis	Liver metastases: 6.1cm (left lobe) 2.9cm (left lobe)	PD CT scan (see Report from 30.04.2002)
CT- Thorax-Abdomen: SD of liver metastasis	Liver metastases: 6.3cm (left lobe) 4.5cm (left lobe)	SD CT scan (see Report from 08.07.2002)
CT- Thorax-Abdomen: SD of liver metastasis	Liver metastases: 6.3cm (left lobe) 4.0cm (left lobe)	SD CT scan (see Report from 02.10.2002)
CT- Thorax-Abdomen: PD of liver metastasis	Liver metastases: 7cm (left lobe) 4.8cm (left lobe)	PD CT scan (see Report from 16.12.2002)

CT- Thorax-Abdomen: SD of liver metastasis Questionable: 4mm lesion left middle lobe of lung	Liver metastases: 7,6x5,7cm (left lobe) Questionable: 4mm lesion left middle lobe of lung	SD liver PD lung? CT scan (see Report from 17.03.2003)
CT- Thorax-Abdomen: PD of liver metastasis SD of 4mm lesion left middle lobe of lung	Liver metastases: New: 2.5cm right liver lobe and 1 small lesion in segment VI ventro-caudal; SD of 4mm lesion left middle lobe of lung	PD liver SD lung CT scan (see Report from 10.06.2003)
CT- Thorax-Abdomen: SD of liver metastasis SD of 4mm lesion left middle lobe of lung	Liver metastases: SD of all lesions; SD of 4mm lesion left middle lobe of lung	SD liver SD lung CT scan (see Report from 08.09.2003)
<b>Patient fit and well, pain free Karnofsky 100%</b>		03.10.2003

Check that the following documents are attached to this Case Report:

Reports

Attached for each date  
patient was evaluated

- 
- a. Full history and physical on first date a response was observed, and all subsequent evaluation dates
  - b. Copies of all x-ray reports and other imaging studies on first date a response was observed and subsequent evaluation dates during and after CAM intervention
  - c. Tumor measurements of all known sites of disease
  - d. Pathology reports of biopsy or autopsy findings any time after initiation of CAM therapy
  - e. Date of last visit and status and/or date and cause of death
- Date of last visit \_\_\_\_ / \_\_\_\_ / \_\_\_\_ Status: **7<sup>th</sup> October 2003: Patient fit and well, Karnofsky 100%**

and/or

Date of death \_\_\_\_ / \_\_\_\_ / \_\_\_\_ Cause of death

Please attach a copy of the note from your office chart documenting this follow-up visit, if available.

- 5. Any toxicity during treatment: No toxicity observed during CAM treatment

**National Cancer Institute's  
Best Case Series Program in Alternative Medicine**

**Case Report Format: Solid Tumors**

Following is a sample case report format that you may use to submit each of your Best Case Series Case Reports regarding an alternative therapy for solid tumors. If you would like an electronic version of this form, contact the OCCAM. You may use a different format for your case reports if you wish, but all of the applicable data listed below must be included.

Patient Name:           A.G.

Diagnosis:   Pancreatic Cancer, Liver Metastasis  

1. Clinical history

a. Date of birth 22.09.1942 *or* age 60 at presentation to your office

b. Sex           Male

c. Date of diagnosis of initial tumor   2<sup>nd</sup> May 2002

How documented?

Histology report from 7<sup>th</sup> May 2002 following Atypical resection of the head of the pancreas:

(1) **Ductal adenocarcinoma of the pancreas,**

(2) **Neuroendocrine tumor components** (confirmed in 2<sup>nd</sup> Histology report from 14<sup>th</sup> May 2002), G2, T1

- d. History of illness with dates of onset of all disease-related symptoms – Please complete Table 1d.

Table 1d. History of Illness

Disease-related symptoms	Date of onset	Treatment	Response
Atypical resection of the head of pancreas with in sano resection of a 4cm tumor which is beginning to infiltrate the d. choledochus and probable infiltration of the vena portae.	2 <sup>th</sup> May 2002	Hepaticojejunoanastomosis and pancreaticojejunostomosis and Braunsch'scher anastomosis	
University hospital including 3 weeks of postoperative ICU due to postoperative bleeding and re-laparotomie; in the last week in ICU end of may 2003 one episode of fever between 38.5-39.0°C with pneumonia due to klebsiella, enterobacter and acinetobacter baumannii: i.v. antibiotics with optinem 3x2g/day	4 <sup>th</sup> May until 20 <sup>th</sup> June 2003	ICU	



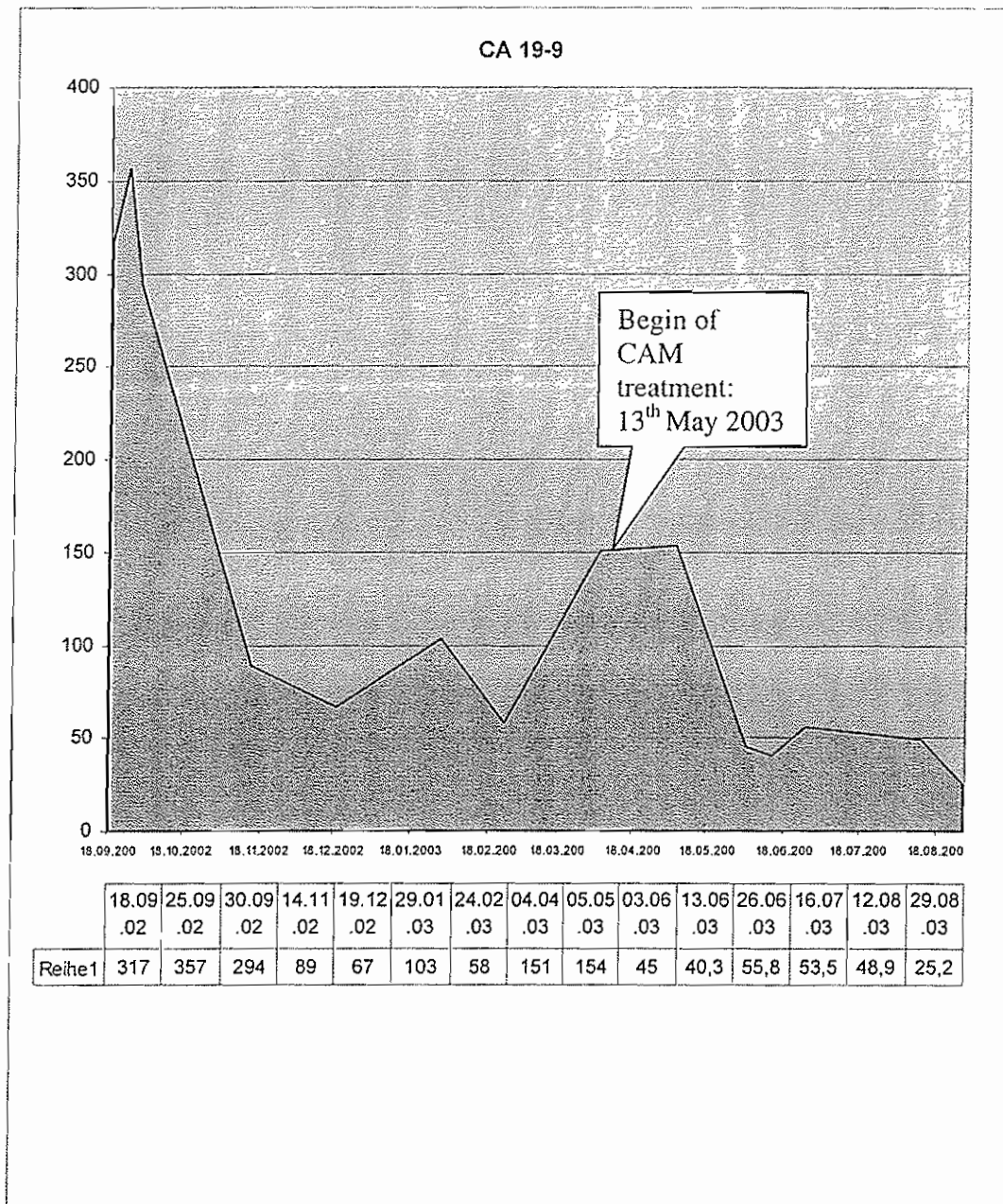
- e. History of prior cancer treatment (if any) – Please complete Table 1e. Provide as much information as possible.

Table 1e. Prior Therapies

Therapy	Practitioner's Name and Contact Information	Dates	Response
23 <sup>rd</sup> September 2002 begin chemotherapy: 6 cycles Gemcitabine 1000mg/m <sup>2</sup> (5cycles), 1800mg/m <sup>2</sup> (1cycle) until mid of January 2003; plan was weekly administration but due to anaemia Chemotherapy was administered only every two to three weeks:	University of Vienna (AKH) Dep. 6i, Oncological Outpatient, Dep. Prof. Dr. Werner Scheithauer, Währinger Gürtel 18-20, A-1090 Vienna, Tel: +43 (1) 40400-4466	23 <sup>rd</sup> September 2002	21 <sup>st</sup> November 2002: restaging CT-Abdomen: <b>PR of liver metastasis,</b> <b>SD of local recurrence,</b> splenomegalie
	University of Vienna (AKH) Dep. 6i...	13 <sup>th</sup> January 2003	13 <sup>th</sup> January 2003: restaging CT-Abdomen: <b>CR of liver metastasis,</b> <b>SD of local recurrence,</b> splenomegalie
4 <sup>th</sup> February 2003 change of chemotherapy: Camptothecin (Irinotecan) 160mg/m <sup>2</sup> , Tomudex 3mg/m <sup>2</sup> : 3 cycles every three weeks until 8 <sup>th</sup> April 2003	University of Vienna (AKH) Dep. 6i...	4 <sup>th</sup> February 2003	31 <sup>st</sup> March 2003: restaging CT-Abdomen: <b>CR of liver metastasis,</b> <b><u>massive PD of local</u></b> <b><u>recurrence,</u></b> <b><u>multiple mesenteric lymph</u></b> <b><u>nodes, progredient ascites,</u></b> <b><u>peritoneal carcinosis,</u></b> <b><u>progredient compression of</u></b> <b><u>bile ducts and compression</u></b> <b><u>of arterial and venous</u></b> <b><u>vessels with consecutive</u></b> <b><u>portal hypertension,</u></b> splenomegalie

Xeloda: 1500mg mornings, 2000mg evenings for two weeks, second cycle was reduced due to massive hand-foot syndrome	University of Vienna (AKH) Dep. 6i...	8 <sup>th</sup> April 2003 until May 2003	PD, massive hand-foot syndrome
Discontinuation of chemotherapy due to massive side effects and PD		11 <sup>th</sup> May 2003	PD
Begin of CAM treatment	Dr. Ralf Kleef	13 <sup>th</sup> May 2003	

Tumor marker CA19-9



2. Disease Prior to CAM Therapy

- a. Results of physical examination just prior to initiation of CAM therapy – Please complete Table 2a.

Table 2a. Physical Examination

Detectable Cancer Sites	Measurement
Clinical massive ascites, splenomegaly, Karnofsky index 50%	Ascites peri-hepatic, perisplenic, mesenteric, filling the pelvis
Diabetes Mellitus II	
Hypertension	

Check that the following documents are attached to this Case Report:

<u>Reports</u>	<u>Attached</u>
b. Pathology report of primary tumor	
c. Pathology reports of recurrent or metastatic disease	
d. Imaging reports (x-ray, CT scans, bone scans, MRI) taken prior to initiation of CAM therapy	

3. Treatment Descriptions

- a. CAM treatment description – Please complete Table 3a. Provide as much information as possible.

Table 3a. CAM Treatment Descriptions

13th Mai 2003 <b>Begin of local hyperthermia treatment</b> with radiofrequency 13,56 MHz, 100 W power for 50 Minutes, <u>3x/weekly</u> for 6 weeks until end of June 2003	Dates 13th Mai 2003 til 30 <sup>th</sup> 2003	Response PR/SD CT scan (see report)
local hyperthermia treatment with radiofrequency 13,56 MHz to <u>2x/weekly</u> until end of July 2003	1 <sup>st</sup> July 2003 til 30th July 2003	PR/SD CT scan (see report)
local hyperthermia treatment with radiofrequency 13,56 M <u>1x/weekly</u> until end of September 2003	1 <sup>st</sup> August 2003 until today	PR/SD CT scan (see report)
<b>Combined with <u>each</u> local hyperthermia treatment</b> with radiofrequency 13,56 MHz intravenous administration of: <b>20mg Ukraine</b> (cheledonium majus, Thiohepa) in NaCl 0.9% 500ml, Vitamine C 10.000mg, HepaMerz (L-Ornithine-L-aspartat 500mg)	13th Mai 2003 til 30 <sup>th</sup> 2003	PR/SD CT scan (see report)

- b. Other concurrent interventions (if any) – Please complete Table 3b. Provide as much information as possible.

Table 3b. Concurrent Interventions

Therapy	Practitioner's Name and Contact Information	Dates
WobeMugos (proteolytic enzymes) 3x3/daily  Aloe Vera	<b>Dr. med. Ralf Kleef</b> Windmühlgasse 30 / 7 / 2 A-1060 Wien Tel: +43 (1) 585-7311 Fax: +43 (1) 585-7311-20 Mobile:+43 (676) 421-3961 Email: <a href="mailto:kleef@hyperthermie.at">kleef@hyperthermie.at</a> <a href="http://www.hyperthermie.at">www.hyperthermie.at</a>	13 <sup>th</sup> May 2003 until today

#### 4. Response to CAM Intervention

If available, please provide bidimensional tumor measurements (largest perpendicular diameters) of all known sites of disease and date of measurement. Completion of this portion of the form is optional but if the patient has had less than a complete remission this information will help in determining the magnitude and duration of the response to therapy.

Table 4a. Radiographic Follow-up

Detectable Cancer Site	Measurement	Date
<b>CT-Abdomen:</b> (1) First diagnosis of <b>carcinosis peritonei</b> , (2) First diagnosis of: <b>tumor reoccurrence of 3x3 cm</b> in the area of the mesenteric trunk (3) First diagnosis of: <b>liver metastasis: multiple up to 1.5cm lesions</b> mostly in the right liver lobe (4) First diagnosis of: <b>Ascites</b>	<b>tumor reoccurrence of 3x3 cm</b>	18 <sup>th</sup> September 2002
<b>Begin of CAM Treatment</b>		13 <sup>th</sup> May 2003
<b>CT-Abdomen:</b> <b>CR of liver metastasis,</b> <b>SD of local recurrence,</b> <b>but progressive ascites,</b> <b>splenomegalie</b>	<b>local recurrence 3x3 cm</b>	2 <sup>nd</sup> June 2003
<b>CT-Abdomen:</b> <b>CR of liver metastasis,</b> <b>SD of local recurrence,</b> <b>nearly complete regression of Ascites,</b> <b>splenomegali</b>	<b>local recurrence 3x3 cm</b>	28 <sup>th</sup> July 2003:
<b>Patient fit and well,</b> <b>Karnofsky 80%</b>		12 <sup>th</sup> September 2003:

Check that the following documents are attached to this Case Report:

Reports

Attached for each date  
patient was evaluated

- 
- a. Full history and physical on first date a response was observed, and all subsequent evaluation dates
  - b. Copies of all x-ray reports and other imaging studies on first date a response was observed and subsequent evaluation dates during and after CAM intervention
  - c. Tumor measurements of all known sites of disease
  - d. Pathology reports of biopsy or autopsy findings any time after initiation of CAM therapy
  - e. Date of last visit and status and/or date and cause of death
- Date of last visit \_\_\_\_ / \_\_\_\_ / \_\_\_\_ Status: **12<sup>th</sup> September 2003: Patient fit and well, Karnofsky 80%**

and/or

Date of death \_\_\_\_ / \_\_\_\_ / \_\_\_\_ Cause of death

Please attach a copy of the note from your office chart documenting this follow-up visit, if available.

- 5. Any toxicity during treatment: No toxicity observed during CAM treatment

# The Clinical Efficacy of Adjuvant Systemic Chemotherapy with Gemcitabine and NSC-631570 in Advanced Pancreatic Cancer

Frank Gansauge<sup>1</sup>, Marco Ramadani<sup>2</sup>, Michael Schwarz<sup>1</sup>, Hans G Beger<sup>1,3</sup>  
Erkki Lotspeich<sup>4</sup>, Bertram Poch<sup>1</sup>

<sup>1</sup>Center for Oncological, Endocrinological and Minimal-access Surgery, <sup>2</sup>Cabion Technologies

<sup>3</sup>Pancreatic Cancer Research Group, University of Ulm, and <sup>4</sup>Army Hospital  
Department of Surgery, Ulm, Germany

Corresponding Author: Dr. Frank Gansauge, Center for Oncological

Endocrinological and Minimal-access Surgery, Silcherstr. 36, 89231 Neu-Ulm, Germany

Tel: +49 731 71576 0, Fax: +49 731 71576 251, E-mail: frank.gansauge@eurosurgery.de

## ABSTRACT

**Background/Aims:** Recently we have shown that NSC-631570 (Ukrain) is a safe and effective drug in the treatment of unresectable pancreatic cancer. The aim of this study was to determine the effectiveness of the combined treatment with Gemcitabine and NSC-631570 in the adjuvant treatment of resected advanced pancreatic cancer.

**Methodology:** 30 patients received adjuvant chemotherapy following surgical resection for pancreatic cancer. Chemotherapy consisted of Gemcitabine according to the Burris-protocol with weekly infusions of 1000mg/sqm. Immediately following Gemcitabine infusion 20mg of NSC-631570 were administered intravenously over 15 minutes.

**Results:** WHO grade II toxicities were observed in 53%, no WHO grade III or IV toxicities occurred. In

80% of the patients recurrence of the disease was observed. The relapse-free survival time was 21.7 months. The actuarial survival rates were 86.7% after one year, 76.6% after two years, 46.7% after three years and 23.3% after five years. The median survival time according to Kaplan-Meier regression analysis was 33.8 months.

**Conclusions:** Adjuvant chemotherapy in advanced stages of pancreatic cancer using the combination of Gemcitabine and NSC-631570 is a safe treatment and seems to lead to a prolonged survival. Although further investigation is needed to confirm these results, the combined treatment of Gemcitabine and NSC-631570 is a promising therapy for the adjuvant treatment of resectable advanced pancreatic cancer.

KEY WORDS:  
AUTHOR please  
provide

## INTRODUCTION

Ductal adenocarcinoma of the pancreas remains one of the most difficult cancers to treat with overall 5-year survival rates of only 0-4% (1) and a 5-year relative survival of 4%. Although 10-15% of patients undergo potentially curative resection of the tumor, with a low postoperative mortality rate, the median survival is only 10-18 months with 5-year survival of 17-24% (2). In patients with node-positive tumors the 5-year survival rate is even lower being less than 10% (3,4). An extensive lymph node dissection does not necessarily result in a favorable prognosis (5). In order to improve patient survival, development of adjuvant chemotherapeutic strategies in addition to surgery is mandatory.

In the palliative treatment of pancreatic cancer systemic chemotherapy using Gemcitabine is the standard first-line therapy (6,7). Recent studies have shown that also in the adjuvant treatment of pancreatic cancer using Gemcitabine has beneficial effects concerning the relapse-free survival as well as the overall survival (8), whereas radiochemotherapy using 5-FU as the chemotherapeutic agent did not lead to

increased survival rates (9).

Recently we have shown that palliative systemic chemotherapy using Gemcitabine and NSC-631570 in unresectable pancreatic cancer increases median survival rates as compared to chemotherapy using Gemcitabine monotherapy (10). In the present study we investigated the use of Gemcitabine and NSC-631570 in the adjuvant situation in patients with advanced pancreatic cancer.

## METHODOLOGY

### Patients and Methods

From November 1999 to May 2002, 30 patients (14 female, 16 male) were included in this study. All patients underwent pancreatic cancer resection with curative intent for locally advanced pancreatic cancer. All patients gave informed consent. 8 Patients were classified UICC stage II, 22 patients were classified UICC stage III. The mean age was 62.3 years ranging from 31 to 78 years. In one patient a resection of the pancreatic tail was performed, 29 patients underwent pancreatic head resection (23 pylorus preserving partial duodenopancreatectomies, 6 partial duodenopan-



**TABLE 1 Side Effects in Patients with Pancreatic Cancer Treated with Gemcitabine and NSC-631570**

	WHO I	WHO II	WHO III
Hematological	42%	29%	0%
Obstipation	3%	0%	0%
Nausea	15%	8%	0%
Diarrhea	17%	4%	0%
Fever	22%	12%	0%

**TABLE 2 Pattern of Relapse and Metastazation in Patients with Pancreatic Cancer Adjuvantly Treated with Gemcitabine and NSC-631570**

Site of relapse	Number of patients	Percent	Time after resection (months)
Local	8/24	33%	23.3
Liver	7/24	29%	16.7
Peritoneum	7/24	29%	23.7
Lymph nodes	7/24	29%	10.2
Lung	3/24	12.5%	34.2
Bone	2/24	16.7%	20.3

createtectomies).

In all patients a R0 resection was performed. In addition an extensive lymph node resection was performed (11). Following resection 24 patients became tumor marker negative, and in 6 patients tumor marker CA19-9 did not return to normal values following resection. Adjuvant chemotherapy consisting of Gemcitabine and NSC-631570 was performed according to a recently published protocol (10) with a mean of 9.8 cycles (range 3-12 cycles). One cycle consisted of weekly infusions of Gemcitabine (1000mg/sqm) and 20mg of NSC-631570 for three weeks followed by one week without therapy. Toxicity was evaluated at every treatment, tumor marker CA19-9 was evaluated at every cycle. Every three months patients were reevaluated according to WHO-criteria, including chest X-ray, ultrasound of the abdomen and CT-scan of the upper abdomen during the first two years, followed by the same examinations every 6 months.

**RESULTS**

**Clinical study:** A mean number of 9.0 cycles (range 3-12 cycles) was applied. There were no drop outs due to serious side effects or interruption of the therapy by the patient. Actually 6 patients are alive more than 5 years following operation for pancreatic cancer without recurrence of the disease.

**Complications related to chemotherapy:** WHO Grade II toxicities were observed in 53% (Table 1). These toxicities were mainly due to hematological reasons. Grade III and grade IV complications were not observed. No skin rash, hair loss, severe fever or stomatitis occurred during the treatment period. Although the treatment of several patients was a little delayed at some time during this study period, chemotherapy was well tolerated and there were no

life-threatening complications. Gastrointestinal bleeding as observed in the previously published study in palliative treatment of pancreatic cancer (10) did not occur.

**Pattern of recurrence and relapse-free survival:** In 24 out of the 30 patients, local recurrence or *metastazation* (AUTHOR is this word correct?) was observed. The sites of recurrences are shown in Table 2. Local recurrence was found in 8 out of these 24 patients. Peritoneal recurrence or recurrence in retroperitoneal lymph nodes was observed in 7 out of these 24 patients. Hepatic metastases were found in 7 patients. Interestingly 2 patients developed bone metastases which is rather rare in pancreatic cancer. Bone metastases especially occurred late following operation and adjuvant chemotherapy (38 and 30.4 months following resection).

In Kaplan-Meier analysis the median relapse-free survival time was 21.7 months (Figure 1). The relapse-free survival rates were 76.6% after one year, 50% after two years, 30% after three years and 20% after five years.

**Survival:** The actuarial survival rates were 86.7% after one year, 76.6% after two years, 46.7% after three years and 23.3% after five years. One patient developed recurrence of the disease 50 months follow-

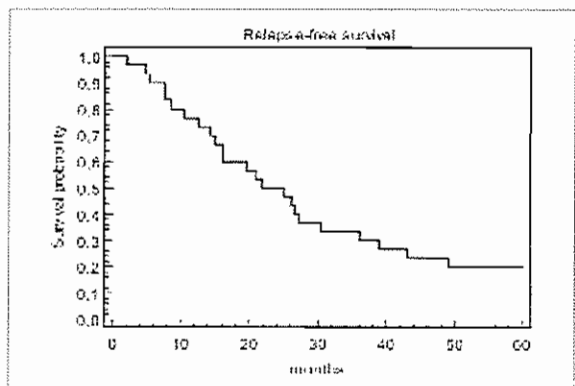


FIGURE 1 The disease-free interval. The disease-free interval following surgery for pancreatic cancer was 21.7 months.

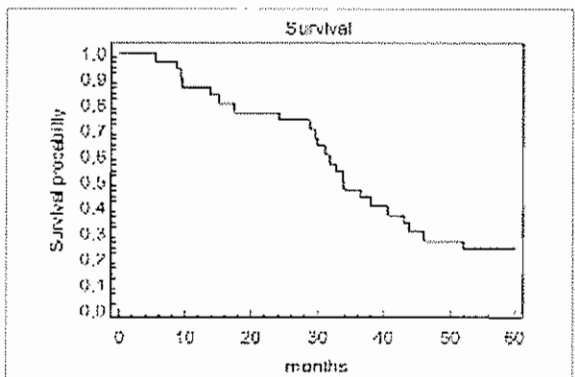


FIGURE 2 Median survival times according to Kaplan-Meier-regression analysis. The median survival time following surgery for pancreatic cancer was 33.8 months. One patient died 62 months following operation; six patients are still alive without recurrence of the disease.

ing operation and died 62 months after operation. The median survival time according to Kaplan-Meier regression analysis was 33.8 months (Figure 2). Six patients (20%) are still alive without recurrence of the disease, more than 5 years after operation.

## DISCUSSION

In advanced pancreatic cancer the lymph node status as well as the extension of the primary tumors are known to be important prognostic factors. Especially lymph node metastases have a negative impact on patients' survival following surgery (12-14). In our study we included only patients showing at least one of these risk factors. Other well known prognostic factors such as extra-pancreatic neural invasion (15) and portal vein involvement (16) were also frequently observed.

Gemcitabine is a promising new agent for the palliative treatment of pancreatic cancer with tolerable toxicity levels, a favorable antitumor activity, and relief of the symptoms related to this very aggressive kind of cancer (6,7). In recent studies the beneficial effect of Gemcitabine in the adjuvant treatment of pancreatic cancer patients following resection has been shown by several investigators (8,9). Recently we have shown that in the palliative treatment of pancreatic cancer the combined therapy with Gemcitabine and NSC-631570 is superior to the Gemcitabine monotherapy without increasing toxicity and side effects of the treatment (10). For this reason we combined adjuvant Gemcitabine treatment with NSC-631570. As in the palliative treatment addition of NSC-631570 to the Gemcitabine chemotherapy did not increase toxicity and all treatments were performed on an outpatient basis. Although 80% of the patients developed recurrence of the disease it is notable, that under this combined treatment the relapse-free survival was prolonged as compared to recently published studies (8,9,17). Even the pattern of recurrence of the disease was different to our observations. *In our study we observed in two of the patients who developed recurrence bone metastases, which is probably due to the fact that this site of metastasation normally needs more time to develop and is covered by peritoneal or hepat-*

**TABLE 3** Analysis of Different Adjuvant Therapies in Advanced Pancreatic Cancer

Author	Year	No. of patients	Therapy	Relapse-free survival	Median survival
Neoptolemos	2001	238	5-FUFS	no data	19.7
Kurosaki	2004	16	Gemzar	16.8	20.4
Gansauge	2006	30	Gemzar/Ukrain	21.7	33.8

*ic metastasation which leads to a fulminant progression of the disease before this metastasation site becomes clinically apparent (AUTHOR please rephrase this sentence to clarify its meaning).* This theory is supported by the observation that bone metastases occurred late after resection of the tumor and adjuvant chemotherapy. With regard to the survival times, 20% of the patients enrolled into this study were disease-free after five years and a median survival time according to Kaplan-Meier regression analysis of 33.8 months was observed. In comparison with other adjuvant chemotherapeutic or radio-chemotherapeutic regimens, the adjuvant treatment using Gemcitabine and NSC-631570 seems to increase postoperative survival times in these patients (Table 3).

Although this monocentric pilot-study enrolled only a small number of patients without comparing different treatment modalities, the combination therapy of the both cytostatic agents Gemcitabine and NSC-631570 seems to be highly effective in the adjuvant treatment of resected pancreatic cancer and these data should be the basis for a randomized study comparing Gemcitabine monotherapy and the combination therapy of Gemcitabine and NSC-631570.

## CONCLUSION

Adjuvant chemotherapy in advanced stages of pancreatic cancer using the combination of Gemcitabine and NSC-631570 is a safe treatment and seems to lead to a prolonged survival. Although further investigation is needed to confirm these results, the combined treatment of Gemcitabine and NSC-631570 is a promising therapy for the adjuvant treatment of resectable advanced pancreatic cancer.

## REFERENCES

- Bramhall SR, Allum WH, Jones AG, Allwood A, Cummins C, Neoptolemos JP: Treatment and survival in 13,560 patients with pancreatic cancer, and incidence of the disease, in the West Midlands: an epidemiological study. *Br J Surg* 1995; 82:111-115.
- Nitecki SS, Sarr MG, Colby TV, van Heerden JA: Long-term survival after resection for ductal adenocarcinoma of the pancreas. Is it really improving? *Ann Surg* 1995; 221:59-66.
- Cameron JL, Crist DW, Sitzmann JV, Hruban RH, Boitnott JK, Seidler AJ, Coleman J: Factors influencing survival after pancreaticoduodenectomy for pancreatic cancer. *Am J Surg* 1991; 161:120-124.
- Baumel H, Huguier M, Manderscheid JC, Fabre JM, Houry S, Fagot H: Results of resection for cancer of the exocrine pancreas: a study from the French Association of Surgery. *Br J Surg* 1994; 81:102-107.
- Kawarada Y, Das BC, Naganuma T, Isaji S: Surgical treatment of pancreatic cancer. Does extended lymphadenectomy provide a better outcome? *J Hepatobiliary Pancreat Surg* 2001; 8:224-229.
- Moore M: Activity of gemcitabine in patients with advanced pancreatic carcinoma. A review. *Cancer* 1996; 78:633-638.
- Burris HA, Moore MJ, Andersen J, Green MR, Rothenberg ML, Modiano MR, Cripps MC, Portenoy RK, Storniolo AM, Tarassoff P, Nelson R, Dorr FA, Stephens CD, Von Hoff DD: Improvements in survival and clinical benefit with gemcitabine as first-line therapy for patients with advanced pancreas cancer: a randomized trial. *J Clin Oncol* 1997; 15:2403-2413.
- Kurosaki I, Hatakeyama K: The clinical efficacy of adjuvant systemic chemotherapy with gemcitabine in node-posi-

- tive pancreatic cancer. *Hepatogastroenterology* 2004; 51:634-637.
- 9 Neoptolemos JP, Dunn JA, Stocken DD, Almond J, Link K, Beger H, Bassi C, Falconi M, Pederzoli P, Dervenis C, Fernandez-Cruz L, Lacaine F, Pap A, Spooner D, Kerr DJ, Friess H, Buchler MW: Adjuvant chemoradiotherapy and chemotherapy in resectable pancreatic cancer: a randomised controlled trial. *Lancet* 2001; 358:1576-1585.
- 10 Gansauge F, Ramadani M, Pressmar J, Gansauge S, Muehling B, Stecker K, Cammerer G, Leder G, Beger HG: NSC-631570 (Ukrain) in the palliative treatment of pancreatic cancer. Results of a phase II trial. *Langenbecks Arch Surg* 2002; 386:570-574.
- 11 Birk D, Beger HG: Lymph-node dissection in pancreatic cancer - what are the facts? *Langenbecks Arch Surg* 1999; 384:158-166
- 12 Beger HG, Rau B, Gansauge F, Poch B, Link KH: Treatment of pancreatic cancer: challenge of the facts. *World J Surg* 2003; 27:1075-1084.
- 13 Delcore R, Rodriguez FJ, Forster J, Hermreck AS, Thomas JH: Significance of lymph node metastases in patients with pancreatic cancer undergoing curative resection. *Am J Surg* 1996; 172:463-468.
- 14 Lygidakis NJ, Papadopoulou P: Pancreatic head carcinoma: is pancreatic resection indicated for patients with stage III pancreatic duct cancer? *Hepatogastroenterology* 1995; 42:587-596.
- 15 Nagakawa T, Kayahara M, Ohta T, Ueno K, Konishi I, Miyazaki I: Patterns of neural and plexus invasion of human pancreatic cancer and experimental cancer. *Int J Pancreatol* 1991; 10:113-119.
- 16 Ishikawa O: Surgical technique, curability and postoperative quality of life in an extended pancreatectomy for adenocarcinoma of the pancreas. *Hepatogastroenterology* 1996; 43:320-325.
- 17 Kosuge T, Kiuchi T, Mukai K, Kakizoe T: A multicenter randomized controlled trial to evaluate the effect of adjuvant cisplatin and 5-fluorouracil therapy after curative resection in cases of pancreatic cancer. *Jpn J Clin Oncol* 2006; 36:159-165.

**AUTHOR PLEASE REPHRASE HIGHLIGHTED SENTENCE PLEASE  
PROVIDE KEY WORDS AND PLEASE CHECK HIGHLIGHTED WORDS  
IN THE TEXT**

## Zentrum für onkologische, endokrinologische und minimalinvasive Chirurgie



Prof. em. Dr. med.  
**Hans G. Beger**  
 Prof. Dr. med.  
**Frank Gansauge**  
 PD Dr. med.  
**Bertram Poch**  
 PD Dr. med.  
**Michael Schwarz**

### Final Report Ukrain Study

**Frank Gansauge, MD, PhD**

Center for Surgical Oncology  
 Silcherstr. 36, 89231 Neu-Ulm

This study started in October 1999. In June 2001 the study was closed, in each arm 30 patients were recruited.

Arm A (Gemcitabine)

Arm B (Ukrain®)

Arm C (Gemcitabine + Ukrain®)

In each study arm 2 drop outs were noted. These patients were not taken into the final results in March 2003.

Regarding the patients data, see publication (Gansauge et al., Langenbeck's Archives of Surgery (2002) 386: 570-574).

In arm A (Gemcitabine monotherapy) all patients have died, in Arm B (Ukrain® monotherapy) 2 patients are alive (7,1%) 26 and 28 months after start of the therapy, in arm C (Gemcitabine + Ukrain®) all patients have died.

Regarding the side effects and the assessment of quality of life see publication (Gansauge et al., Langenbeck's Archives of Surgery (2002) 386: 570-574).

■ **Illertalklinik**  
 Abt. Viszeralchirurgie  
 Krankenhausstraße 7  
 89257 Illertissen  
 Tel. FAX: +49 (0) 7107 - 177 183  
 clinic@viszeralchirurgie.de

■ **Praxis**  
 Silcherstraße 36  
 89231 Neu-Ulm  
 Tel. +49 (0) 731 - 715 76 0  
 Fax +49 (0) 731 - 715 76 250  
 info@viszeralchirurgie.de

**Median Survival (Kaplan-Meier-Lifetime analysis)**

Arm A (Gemcitabine monotherapy)	4,8	months
Arm B (Ukrain® monotherapy)	8,1	months
Arm C (Gemcitabine + Ukrain®)	9,3	months

**Significance levels (Chi-square-test)**

Arm A versus Arm B:	$p < 0,01$
Arm A versus Arm C:	$p < 0,02$
Arm B versus Arm C:	not significant ( $p=0,67$ )

**Survival rates**


	6 months	,9 months	12 months	24 months
Arm A	32%	11%	11%	0%
Arm B	61%*	43%**	32%	18%
Arm C	64%*	54%**	29%	4%

### Summary and Conclusion

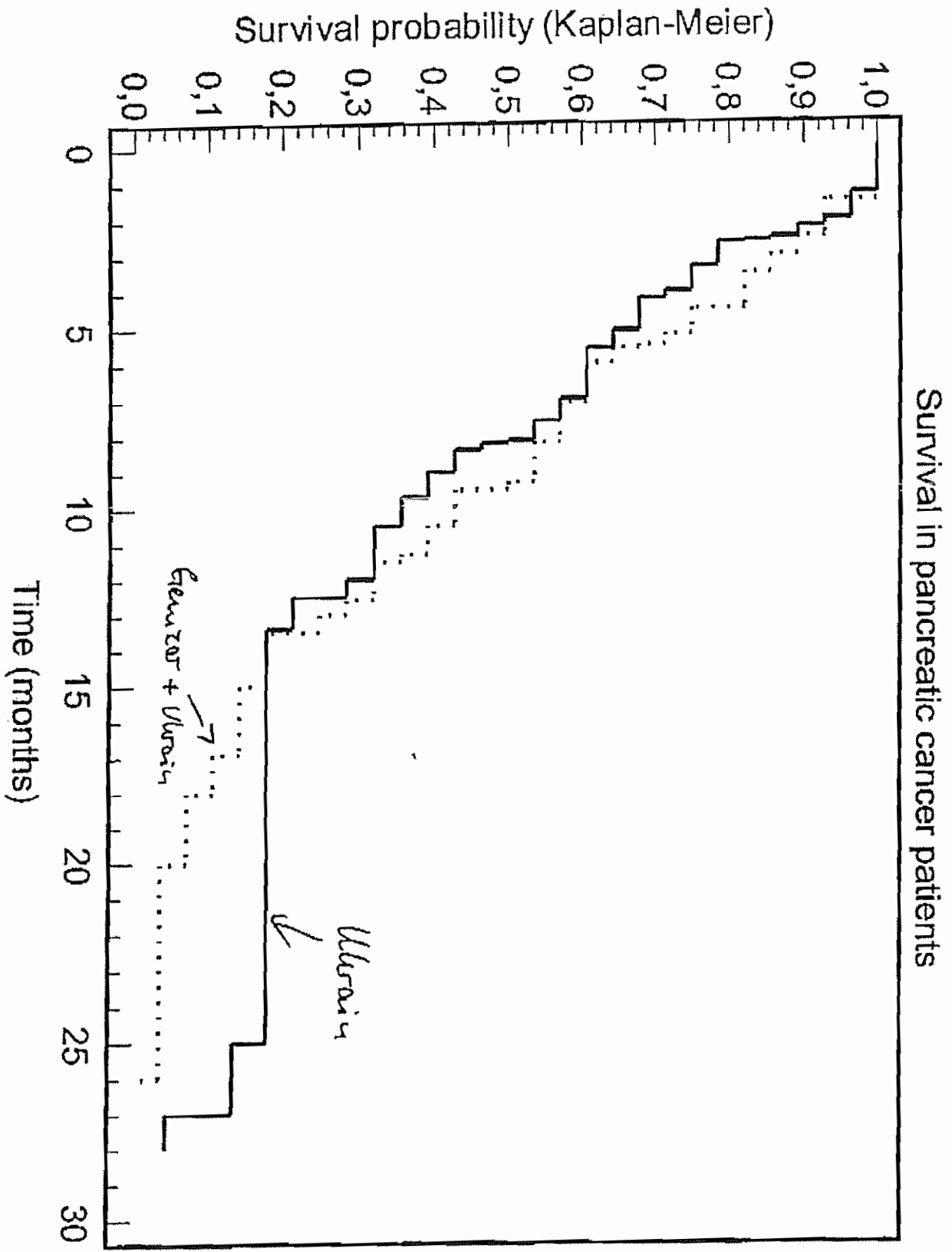
In this analysis at the end of the study „Ukrain® in the palliative treatment of advanced pancreatic cancer patients“ the preliminary results were confirmed. The median survival times in arm C were reduced as compared to the study results 18 months ago, whereas median survival times remained unchanged in arm A and arm B.

Ukrain® proofed to be well tolerated and can be used easily on an outpatient basis. In the study arms containing Ukrain® the median survival times were significantly prolonged as compared to the Gemcitabine monotherapy arm. The combination of Gemcitabine with Ukrain® showed no significant advantage as compared to the Ukrain® monotherapy arm. As the result of this study we highly recommend the treatment of patients suffering from advanced pancreatic cancer with Ukrain®.

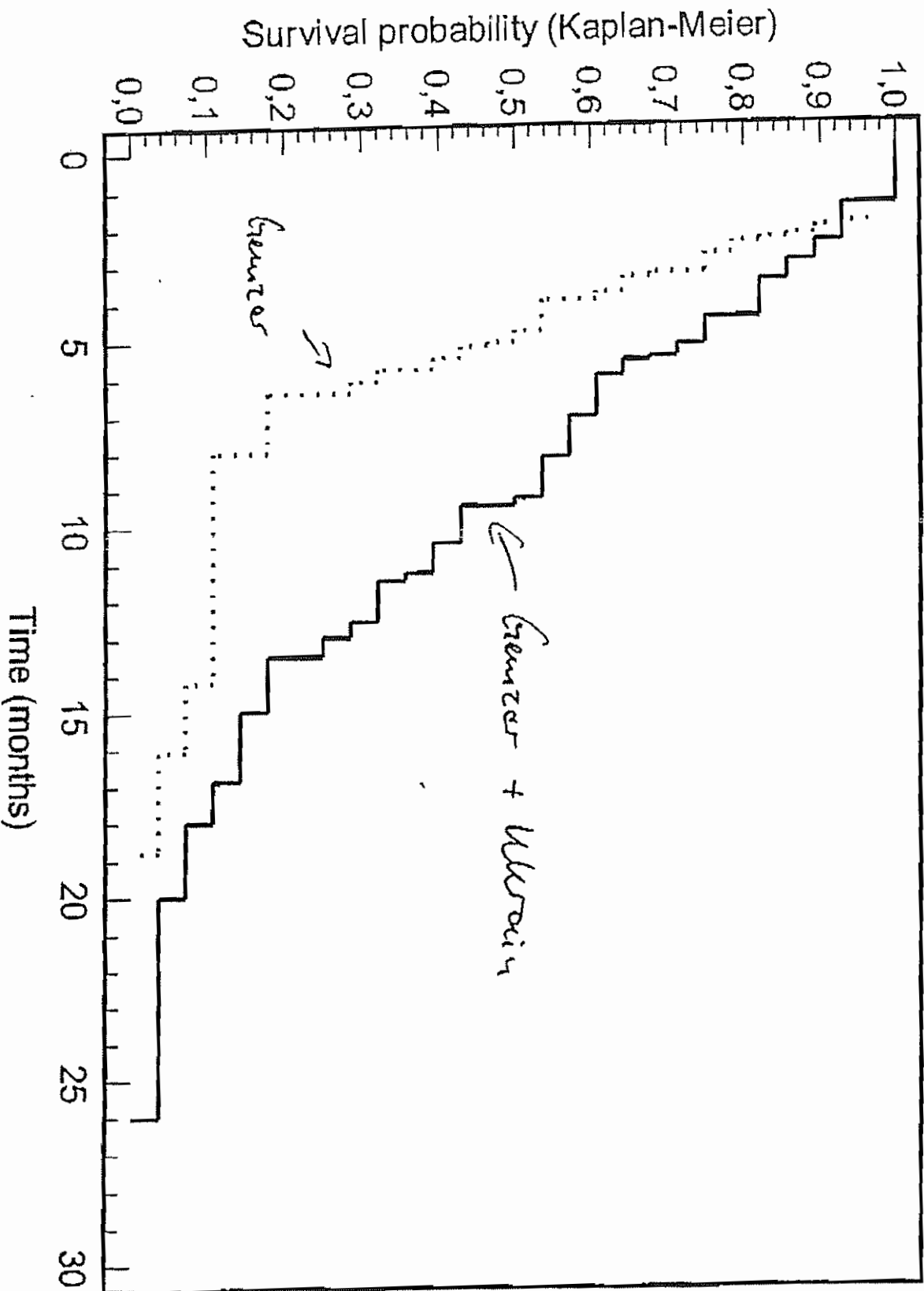
Neu-Ulm, 13.03.2003



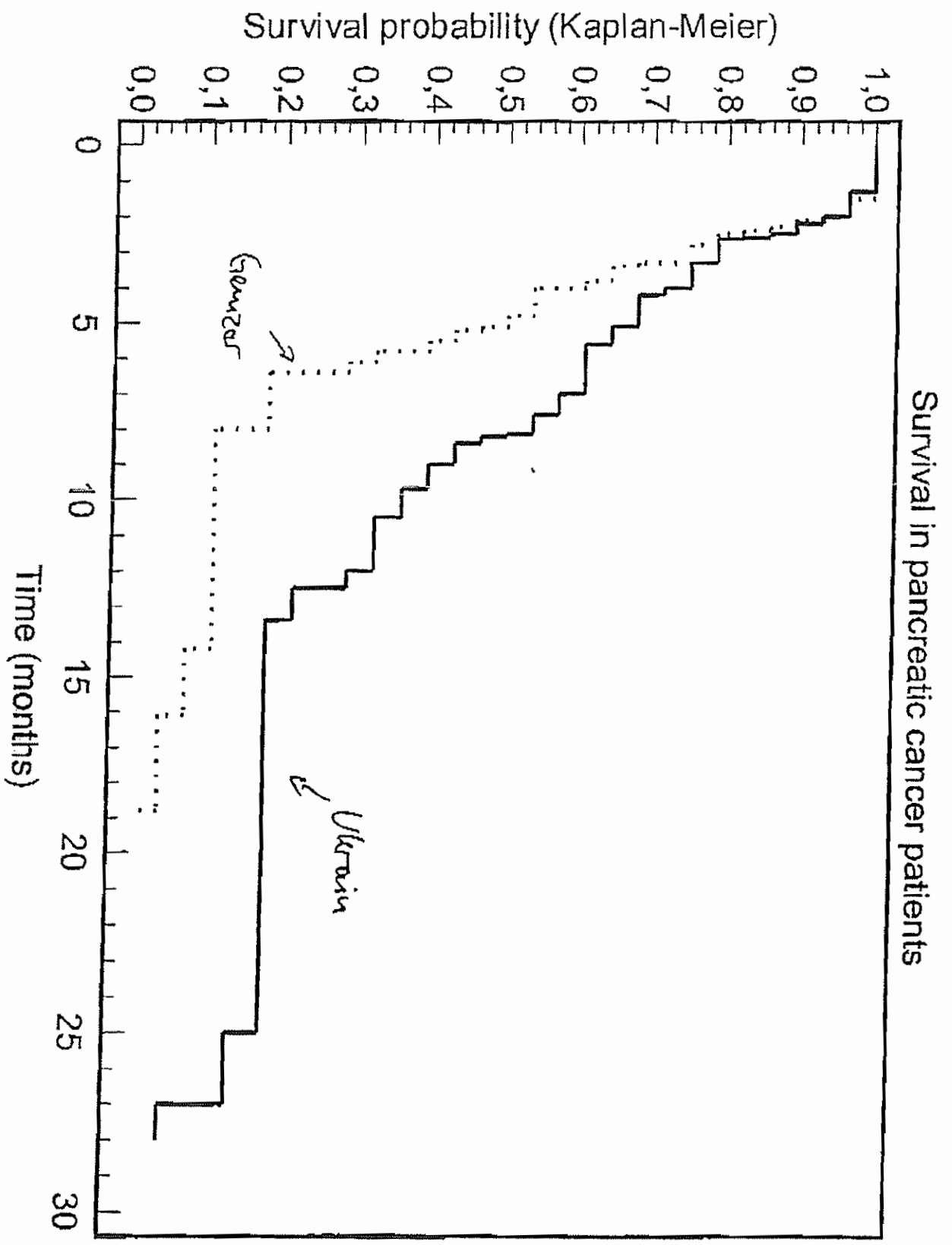
Frank Gansauge, MD, PhD



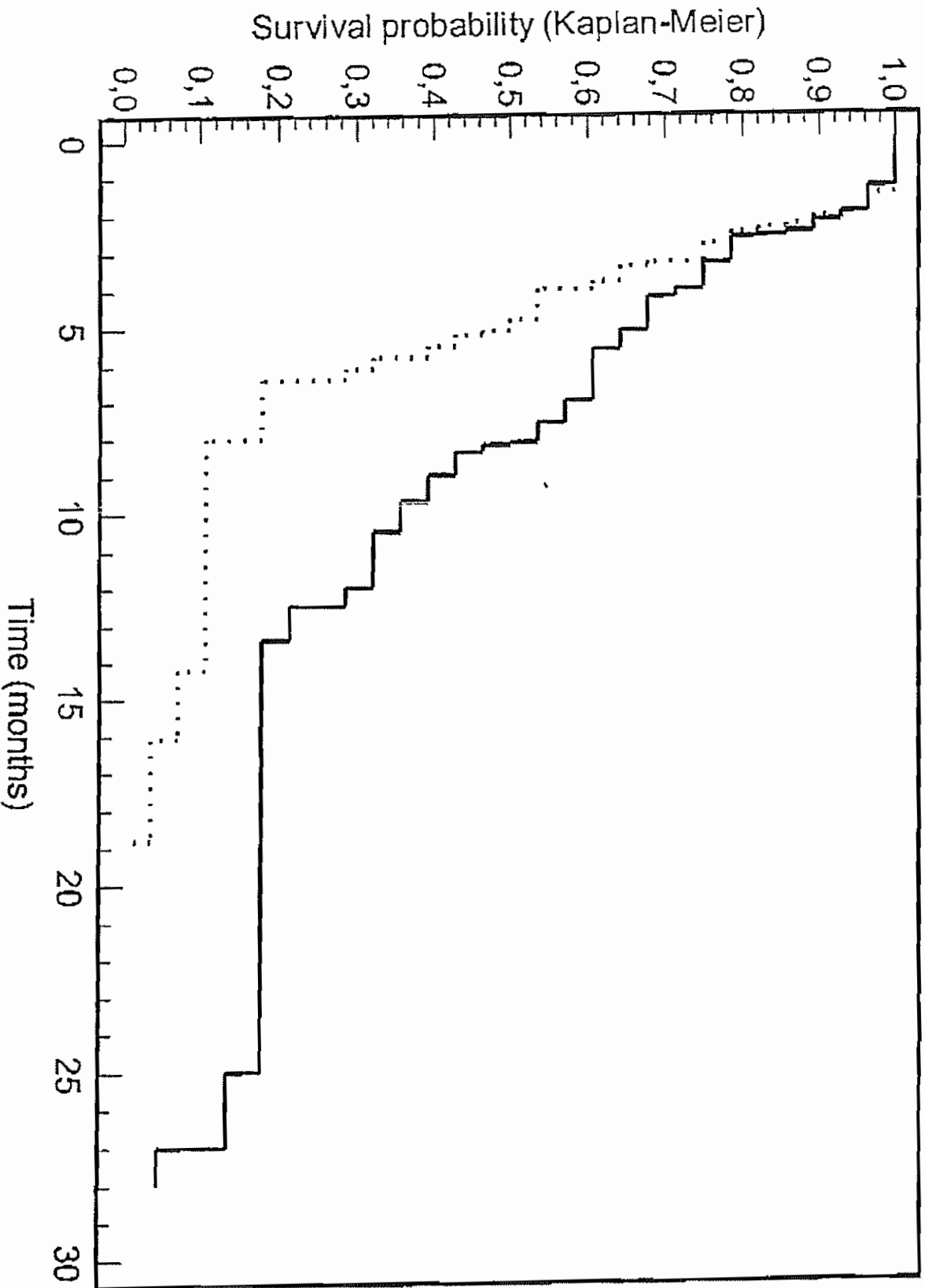
# Survival analysis in pancreatic cancer patients



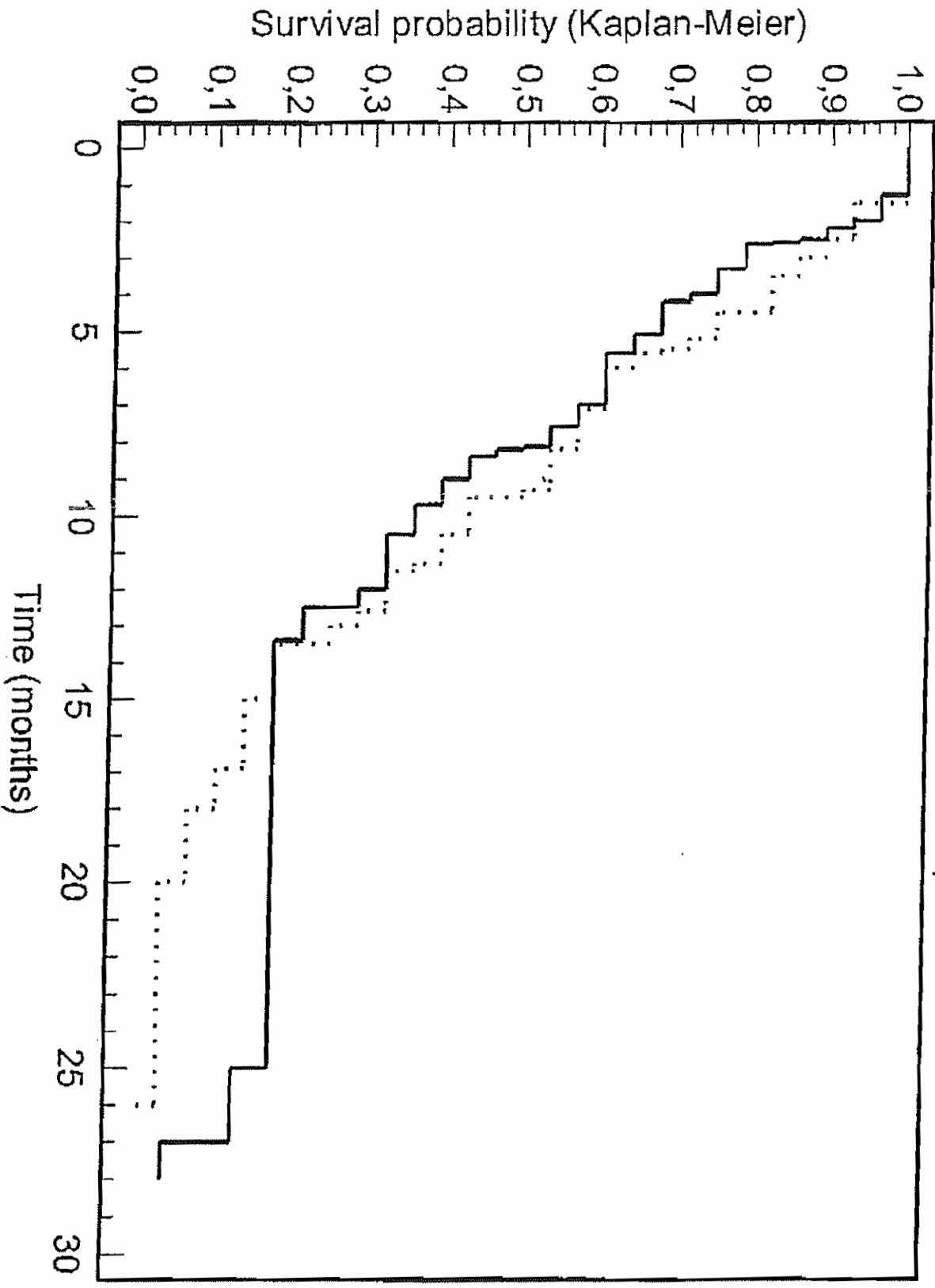




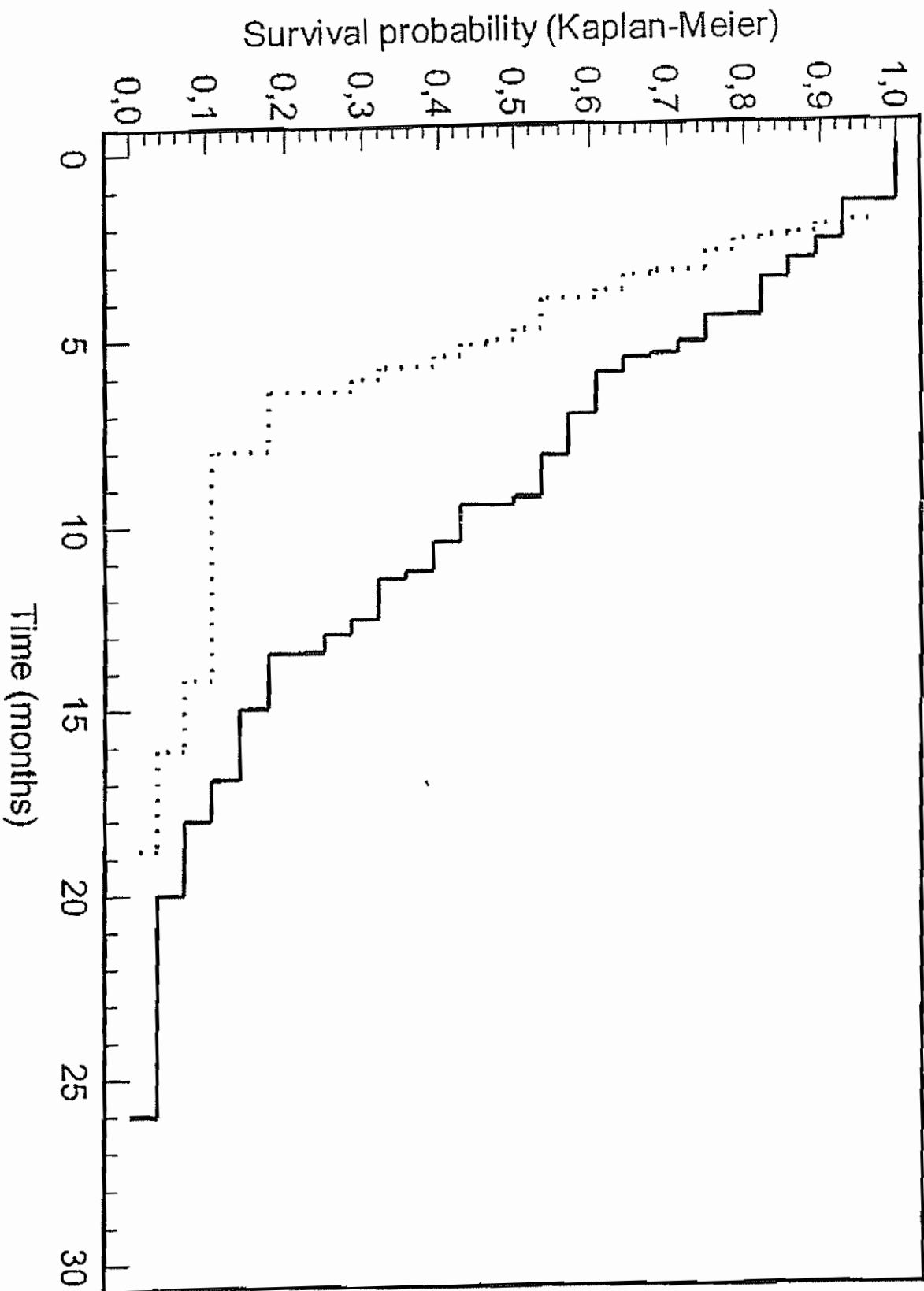
Survival in pancreatic cancer patients



# Survival in pancreatic cancer patients



Survival analysis in pancreatic cancer patients



Frank Gansauge  
Marco Ramadani  
Jochen Pressmar  
Susanne Gansauge  
Bernd Muehling  
Kerstin Stecker  
Gregor Cammerer  
Gerd Leder  
Hans G. Beger

## NSC-631570 (Ukrain) in the palliative treatment of pancreatic cancer

### Results of a phase II trial

Received: 10 September 2001  
Accepted: 27 November 2001  
Published online: 13 February 2002  
© Springer-Verlag 2002

F. Gansauge · M. Ramadani · J. Pressmar  
B. Muehling · K. Stecker · G. Cammerer  
G. Leder · H.G. Beger (✉)  
Department of General Surgery,  
University of Ulm, Germany  
e-mail: hans.beger@medizin.uni-ulm.de  
Tel.: +49-731-50026780  
Fax: +49-731-50026787

H.G. Beger  
Professor for Surgery, University of Ulm,  
Steinhoevelstrasse 9, 89075 Ulm, Germany

F. Gansauge · M. Ramadani · S. Gansauge  
H.G. Beger  
bio.Venture Technologies,  
Rechbergweg 31, 89075 Ulm, Germany

M. Ramadani · S. Gansauge  
Division of Molecular Oncology,  
Department of General Surgery,  
University of Ulm, Germany

**Abstract** *Background:* NSC-631570 (Ukrain) is a semisynthetic compound of thiophosphoric acid and the alkaloid chelidonine from the plant *Chelidonium majus*. It has been used in complementary herbal medicine for more than 20 years for the treatment of benign and malignant tumors. *Patients/methods:* Between August 1999 and June 2001, 90 patients with histologically proven unresectable pancreatic cancer were randomized in a monocentric, controlled, randomized study. Patients in arm A received 1000 mg gemcitabine/m<sup>2</sup>, those in arm B received 20 mg NSC-631570, and those in arm C received 1000 mg gemcitabine/m<sup>2</sup> followed by 20 mg NSC-631570 weekly. End point of the study was overall survival.

*Results:* In all three arms therapy was well tolerated and toxicity was moderate. At the first re-evaluation in arm A 32%, in arm B 75%, and in

arm C 82% showed no change or partial remission according to WHO criteria (arm A versus arm B:  $P < 0.01$ , arm A versus arm C:  $P < 0.001$ ). Median survival according to Kaplan-Meier analysis was in arm A 5.2 months, in arm B 7.9 months, and in arm C 10.4 months (arm A versus arm B:  $P < 0.01$ , arm A versus arm C:  $P < 0.01$ ). Actuarial survival rates after 6 months were 26%, 65% and 74% in arms A B and C, respectively (arm A versus arm B:  $P < 0.05$ , arm A versus arm C:  $P < 0.01$ ). *Conclusion:* We could show that in unresectable advanced pancreatic cancer, NSC-631570 alone and in combination with gemcitabine nearly doubled the median survival times in patients suffering from advanced pancreatic cancer.

**Keywords** Pancreatic cancer · Chemotherapy · Gemcitabine · NSC-631570 · Ukrain

### Introduction

So far, no highly effective treatment for advanced pancreatic cancer has been established. During the past years, gemcitabine was found to have a positive influence on the quality of life in pancreatic cancer patients palliatively treated with weekly infusions of gemcitabine; however, median survival times in patients treated with gemcitabine were only marginally prolonged [1]. Protocols using combinations of gemcitabine with 5-FU with or without folinic acid or combinations of gemcitabine and cisplatinium have prolonged median survival

up to 8.3 months [2, 3, 4]. Additional radiation therapy in combination with mitomycin C and gemcitabine did not significantly improve survival [5]. In our clinic we used intra-arterial infusions of the celiac trunk using 5-FU, mitoxantrone and cisplatinium and observed an improvement in survival; however, this treatment of regional chemotherapy is associated with long periods of hospitalization [6].

Several plant-derived drugs are used in medical oncology. The greater celandine (*Chelidonium majus* L.) is a member of the Papaveraceae family and is a common weed in Europe and Western Asia [7]. For many centu-

ries the plant has been used in the therapy of warts, skin cancers, and liver and gallbladder diseases, and the major component of the wide variety of alkaloids found in this plant is chelidonium [8]. NSC-631570 (Ukraine) is a semisynthetic compound of thiotepa and the alkaloid chelidonium from the plant *Chelidonium majus*. NSC-631570 is thought to consist of 1 molecule thiophosphoric acid (thiotepa) conjugated to 3 molecules of chelidonium. It has been used in alternative medicine as an anti-cancer drug for more than 20 years without knowledge of the mechanism of its action. However, several promising case reports exist on the antitumoral effects of NSC-631570 in cancer patients [9, 10, 11, 12].

The aim of this study was to evaluate the clinical use of this plant-derived drug by means of intravenous therapy in the treatment of unresectable, highly advanced pancreatic cancer in a monocentric, controlled, randomized study.

## Patients and methods

Monocentric, controlled, randomized study

Between August 1999 and June 2001, a total of 90 patients were recruited into the prospective, controlled, monocentric, randomized study. The study protocol was approved by the local ethics committee. Gemcitabine was supplied by Lilly (Giessen, Germany). NSC-631570 was generously provided by Nowicky Pharma (Vienna, Austria). Inclusion criteria were histologically proven unresectable adenocarcinoma of the pancreas. Exclusion criteria were age below 18 years, pregnancy or lack of contraception, oth-

er cancer diseases, viral infection with hepatitis B or C or HIV, immunosuppressive therapy, or diseases of the central nervous system. All patients gave informed consent to participation in the study prior to treatment. Therapy was reduced by 20% in cases of WHO grade II toxicities; in cases of WHO grade III toxicities therapy was interrupted until toxicity had normalized and was then continued with a dose reduction of 20%. In arm A, 30 patients received 1000 mg gemcitabine/m<sup>2</sup> weekly, according to the protocol recently published by Burris [1] (first cycle: 7 weeks of therapy, 1 week of rest; 2nd–12th cycles: 3 weeks of therapy, 1 week of rest). In arm B, 30 patients received 20 mg NSC-631570 weekly (first cycle: 7 weeks of therapy, 1 week of rest; 2nd–12th cycles: 3 weeks of therapy, 1 week of rest), and in arm C, 30 patients received 1000 mg gemcitabine/m<sup>2</sup> followed by 20 mg NSC-631570 weekly (first cycle: 7 weeks of therapy, 1 week of rest; 2nd–12th cycles: 3 weeks of therapy, 1 week of rest). In arms B and C in the first week of the first cycle, NSC-631570 was administered during the first 5 days at a daily dose of 20 mg per day. In all three arms, most of the patients received supplementary vitamins, especially vitamin C. During the first week of therapy the patients were treated as in-house patients; the following therapies were performed in the out-patient department. After 3, 6, 9, and 12 months, patients were re-evaluated according to WHO criteria, including chest X-ray, ultrasound of the abdomen and CT scan of the upper abdomen. Quality of life was assessed by the EORTC-QLQ-C30 Version 3.0. Patients who died prior to the first re-evaluation were considered PD (progressive disease). Tumor marker CA19-9 was evaluated at every treatment. Tumor marker response at the first restaging examination at 3 months was defined as follows: complete response (CR) = normalization of CA19-9 for more than 4 weeks, partial response (PR) = reduction of CA19-9 by more than 50% for 4 weeks, no change (NC) = no reduction >50% or elevation >50%, and progressive disease (PD) = elevation of CA19-9 by more than 50%. At each application toxicity and side effects were evaluated. The patients' characteristics are shown in Table 1. In each arm, 30 patients had been randomized.

**Table 1** Patients receiving palliative chemotherapy. UICC Union Internationale Contra la Cancrum (International Union Against Cancer)

	Arm A Gemcitabine	Arm B NSC-631570	Arm C NSC-631570/gemcitabine
Number of patients	30	30	30
Mean age (range)	63.8 (53–79)	60.6 (40–80)	58.2 (22–74)
Sex			
Female	8	14	11
Male	22	16	19
Mean number of cycles (SD)	3.8 (3.1)	5.6 (3.9)	6.8 (3.9)*
UICC stage			
Stage 3	1	0	1
Stage 4a	12	13	7
Stage 4b	17	17	22
Recurrence	5	7	6
Metastases			
Hepatic	11	9	9
Peritoneal	5	5	5
Hepatic + peritoneal	1	5	8
Pulmonal	1	0	0
Other therapies prior to randomization			
Chemotherapy	1	1	3
Radiochemotherapy	1	4	2
Drop outs	2	2	2

\*Significant as compared to arm A ( $P < 0.005$ )

**Table 2** Side effects in palliatively treated pancreatic cancer patients

	Gemcitabine Arm A			NSC-631570 Arm B			NSC-631570/gemcitabine Arm C		
	WHO I	WHO II	WHO III	WHO I	WHO II	WHO III	WHO I	WHO II	WHO III
Hematological	46%	13%	12%	25%	7%	11%	43%	32%	10%
Obstipation	0%	27%	0%	3%	3%	2%	3%	3%	1%
Nausea	9%	33%	11%	16%	3%	3%	18%	6%	3%
Diarrhea	18%	9%	2%	14%	10%	1%	16%	5%	0%
Fever	13%	9%	0%	22%	20%	0%	18%	16%	0%
Tumor bleeding		0%			7%			7%	

## Results

### Clinical study

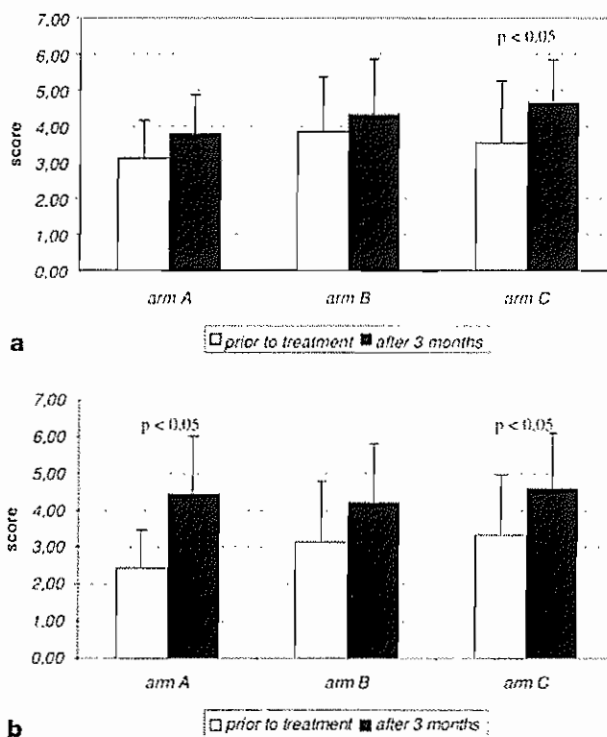
In the gemcitabine monotherapy arm 25/30 patients had died, 2/30 patients had interrupted therapy and 3/30 patients are still under therapy. In the patients who finished therapy, a mean number of 3.8 cycles (SD: 3.1, ranging from 1 to 12 cycles) were applied. In the NSC-631570-monotherapy arm, 12/30 patients had died, 3/30 patients are alive after 12 cycles. 2/30 patients had interrupted therapy, and 13/30 patients are still under therapy. In the patients who finished therapy, a mean number of 5.6 cycles (SD: 3.9, ranging from 1 to 12 cycles) were applied. In the gemcitabine/NSC-631570 arm, 19/30 patients had died, 2/30 patients had interrupted therapy, 2/30 patients are alive after 12 cycles of therapy, and 7/30 patients are still under therapy. Compared with the gemcitabine monotherapy arm, significantly more cycles were applied in the gemcitabine/NSC-631570 arm (3.8 versus 6.8 cycles,  $P < 0.005$ ).

### Side effects

In all three arms therapy was well tolerated and no severe side effects occurred. In no patient was it necessary to stop the therapy because of harmful side effects. In arm A nausea seemed to be more frequent than in arm B and arm C ( $P < 0.05$ ), whereas in arm B and arm C fever was observed more frequently ( $P < 0.05$ ). In arm C (gemcitabine plus NSC-631570) hematological toxicities WHO II occurred with significantly more frequency than in arm A and arm B ( $P < 0.05$ ). Increases in liver enzymes occurred in all three arms at the same frequency and were related to stent occlusion or disease progression of hepatic metastases. In four patients tumor bleeding occurred (two patients in arm B, two patients in arm C), which were treated by angiographic intervention. The side effects are shown in Table 2.

### Quality of life

Quality of life was assessed by the EORTC-QLQ-C30 questionnaire prior to the beginning of treatment, and



**Fig. 1** Self-estimation of the health status (a) and the quality of life status (b) in palliatively treated pancreatic cancer patients prior to treatment and after 3 months of therapy. a With regard to the self-estimation of the health status a significant difference was observed in arm C, and b with regard to the self-estimation of the quality of life status a significant improvement was observed in arm A and arm C

then every 3 months. In all three therapy arms no significant differences were observed between the start of the therapy and after 3 months concerning the first 28 questions. With regard to the last two questions concerning the self-estimation of the health status (question 29) and the self-estimation of the quality of life status (question 30), a significant improvement was noted in arm A and arm C (Fig. 1).

**Table 3** Response and survival in palliatively treated pancreatic cancer patients

	Arm A Gemcitabine	Arm B NSC-631570	Arm C NSC-631570 / gemcitabine
Tumor marker response			
Complete response	1/15	0/15	1/20
Partial response	5/15	4/15	7/20
No change	5/15	5/15	9/20
Progressive disease	4/15	5/15	3/20
Response after 3 months			
Complete response	0/28	0/20	0/28
Partial response	1/28	2/20	6/28
No change	8/28	13/20	17/28
Progressive disease	19/28	5/20	5/28
CR+PR+NC versus PD	9/19	15/5**	23/5***
Survival			
Survival rate (6 months)	26%	65%*	74%**
Survival rate (9 months)	13%	40%	56%**
Survival rate (12 months)	13%	29%	32%
Median survival (months)	5.2	7.9**	10.4**

\* $P < 0.05$  as compared to gemcitabine Monotherapy (arm A)

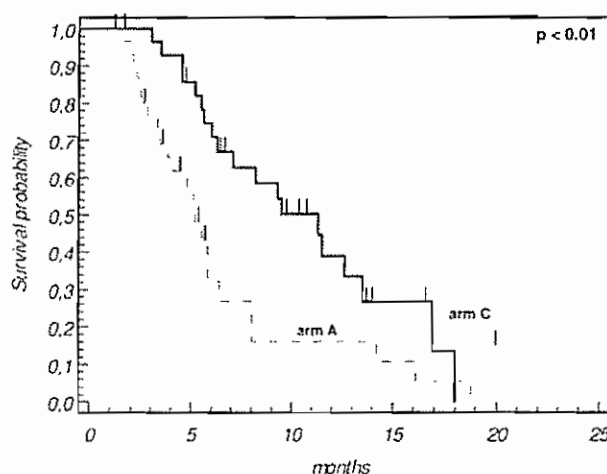
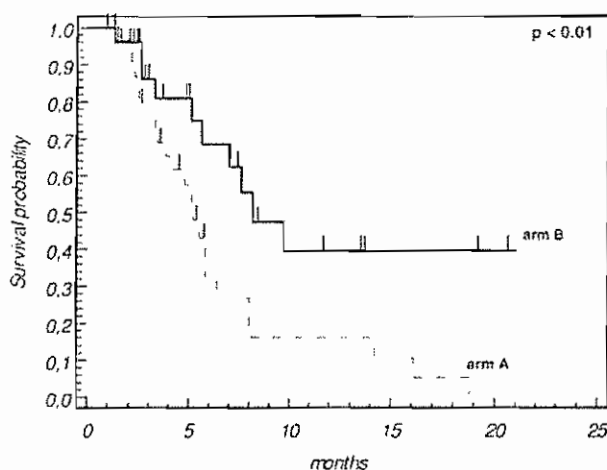
\*\* $P < 0.01$  as compared to gemcitabine Monotherapy (arm A)

\*\*\* $P < 0.001$  as compared to gemcitabine Monotherapy (arm A)

#### Response and survival

In all three groups the tumor marker response at the first restaging examination was comparable. According to the CA19-9 levels, disease was only progressive in 27%, 33% and 15% of the patients in arm A B and C, respectively. However, it has to be noted that only patients that had elevated CA19-9 serum levels and patients who underwent re-examination were evaluated, whereas patients who did not have elevated CA19-9 serum levels and patients who died prior to the first re-examination were not evaluated.

According to WHO criteria, patients were examined after 3 months of therapy. In both arm A and arm C two patients had stopped therapy prior to the first re-evaluation; in arm B one patient had stopped therapy and nine patients are under therapy without having reached the third month of therapy. No case of complete response according to CT scan was observed. In arm B and arm C significantly more patients showed partial response or no



**Fig. 2a,b** Kaplan-Meier survival curves of advanced pancreatic cancer patients palliatively treated according to arm A, arm B, or arm C. **a** Patients who received NSC-631570 monotherapy (arm B, solid line) lived significantly longer as compared to patients treated with gemcitabine monotherapy (arm A, dashed line). Median survival times were arm A 5.2 months, arm B 7.9 months ( $P < 0.01$ ). **b** Patients who received NSC-631570 plus gemcitabine (arm C, solid line) lived significantly longer than patients with gemcitabine monotherapy (arm A, dashed line). Median survival times in arm C were 10.4 months ( $P < 0.01$ ). No statistically significant difference was found between median survival times in arm B and arm C



change after 3 months of therapy as compared to arm A (PR + NC: arm A 32%, arm B 75%, arm C 82%; arm A versus arm B:  $P < 0.01$ ; arm A versus arm C:  $P < 0.001$ , chi-squared test) (Table 3).

Regarding actuarial survival rates and median survival times, patients in arm B and arm C lived significantly longer than patients in arm A. The actuarial survival rates after 6 months were in arm A 26%, in arm B 65%, and in arm C 74% (arm A versus arm B:  $P < 0.05$ ; arm A versus arm C:  $P < 0.01$ ; arm B versus arm C: not significant). Even after 9 months the actuarial survival in arm C was still significant as compared to arm A (56% versus 13%,  $P < 0.01$ ) (Table 3). These increased survival rates were also reflected in the median survival times according to Kaplan-Meier regression analysis. The median survival rate was significantly higher in arm B and arm C (7.85 months and 10.4 months) as compared to arm A (5.15 months,  $P < 0.01$  and  $P < 0.01$ , respectively) (Table 3, Fig. 2).

## Discussion

Since NSC-631570 has been used in a wide variety of cancers and has been described as a potent anticancer drug with minimal side effects, we performed a phase II study in unresectable advanced pancreatic cancer patients. In this controlled, randomized study, patients were treated either with gemcitabine, which is the most commonly used treatment in this disease, or with NSC-631570 or with gemcitabine plus NSC-631570. In the

gemcitabine monotherapy arm (arm A) our findings were very similar to the data published by Burris and colleagues – that gemcitabine led to an increase in the quality of life and to a marginal increase in median survival times [1], whereas in the NSC-631570 monotherapy arm (arm B) only a statistically insignificant increase in the quality of life was observed. A combination of the two also led to an increase in the quality of life. Regarding the side effects, all three arms showed moderate side effects. It is noteworthy that in both the arms containing NSC-631570, in two cases tumor-bleeding into the duodenum occurred, which had to be treated angiographically. Very recently, cases of acute hepatitis under the treatment with plant extracts of greater celandine have been reported [13]. In our study we observed in all three arms several times cholangitis with increases in liver enzymes; however, in all cases an incrustation of a stent or occlusion of the common bile duct by tumor masses turned out to be the reason. Interestingly, median survival times were significantly longer in both arms containing NSC-631570 (arm B and arm C) as compared to the gemcitabine monotherapy arm (arm A), suggesting that NSC-631570 acts as a potent drug in the treatment of unresectable advanced pancreatic cancer.

In conclusion, we were able to show that in unresectable advanced pancreatic cancer, and in combination with gemcitabine, NSC-631570 nearly doubled the median survival times in these patients. However, since side effects such as tumor bleeding occurred under the treatment with NSC-631570, cancer treatment using this potent drug should be performed under medical control.

## References

- Burris H, Moore M, Andersen J, Green M, Rothenberg M, Modiano M, Cripps M, Portenoy R, Storniolo A, Tarassoff P, et al (1997) Improvements in survival and clinical benefit with gemcitabine as first-line therapy for patients with advanced pancreatic cancer: a randomized trial. *J Clin Oncol* 15:2403–2413
- Oettle H, Arning M, Pelzer U, Arnold D, Stroszczyński C, Langrehr J, Reitzig P, Kindler M, Herrenberger J, Musch R, et al (2000) A phase II trial of gemcitabine in combination with 5-fluorouracil (24-hour) and folinic acid in patients with chemo-naïve advanced pancreatic cancer. *Ann Oncol* 11:1267–1272
- Kurtz J, Kohser F, Negrier S, Trillet Lenoir V, Walter S, Limacher J, Untereiner M, Kayitalire L, Jaeck D, Dufour P (2000) Gemcitabine and protracted 5-FU for advanced pancreatic cancer. A phase II study. *Hepatogastroenterology* 47:1450–1453
- Heinemann V (2001) Gemcitabine: progress in the treatment of pancreatic cancer. *Oncology* 60:8–18
- Kornek G, Potter R, Selzer E, Schratzer A, Ulrich Pur H, Rogy M, Kraus G, Scheithauer W (2001) Combined radiochemotherapy of locally advanced unresectable pancreatic adenocarcinoma with mitomycin C plus 24-hour continuous infusional gemcitabine. *Int J Radiat Oncol Biol Phys* 49:665–671
- Gansauge F, Link K, Rilinger N, Kunz R, Beger H (1995) Regionale Chemotherapie beim fortgeschrittenen Pankreaskarzinom. [Regional chemotherapy in advanced pancreatic carcinoma]. *Med Klin* 90:501–505
- Colombo ML, Bosisio E (1996) Pharmacological activities of *Chelidonium majus* L. (Papaveraceae). *Pharmacol Res* 33:127–134
- Kreitmeir H. (1950) *Chelidonium majus* L. – das Schöllkraut. *Pharmazie* 5:85–88
- Vyas JJ, Jain VK (1996) Ukrain treatment in carcinoma of the oesophagus (case report). *Drugs Exp Clin Res* 22:267–269
- Lohninger A, Korsh OB, Melnyk A (1996) Combined therapy with Ukrain and chemotherapy in ovarian cancer (case report). *Drugs Exp Clin Res* 22:259–262
- Kadan P, Korsh OB, Melnyk A (1996) Ukrain therapy of recurrent breast cancer with lung metastases (case report). *Drugs Exp Clin Res* 22:243–245
- Hamler F, Hiesmayr W, Korsh OB, Melnyk A. (1996) Ukrain monotherapy in malignant melanoma (case report). *Drugs Exp Clin Res* 22:235–237
- Benninger J, Schneider H, Schuppan D, Kirchner T, Hahn E (1999) Acute hepatitis induced by greater celandine (*Chelidonium majus*). *Gastroenterology* 117:1234–1237

Volodimir Zemskov  
Olga Prokopchuk  
Yaroslav Susak  
Sergiy Zemskov  
Olexander Tkachenko  
Yuriy Hodysh  
Wassil Nowicky

## Efficacy of Ukrain in the treatment of pancreatic cancer

Received: 24 March 2002  
Accepted: 4 April 2002  
Published online: 19 June 2002  
© Springer-Verlag 2002

V. Zemskov · O. Prokopchuk (✉)  
Y. Susak · S. Zemskov · O. Tkachenko  
Department of General Surgery,  
National Medical University,  
prosp. Holosiivsky, 59B, 03039 Kyiv,  
Ukraine  
e-mail:  
olga.prokopchuk@medizin.uni-ulm.de  
Tel.: +49-731-50027217  
Fax: +49-731-50021593

O. Prokopchuk  
Department of Visceral and  
Transplantation Surgery, Ulm University,  
Steinhövelstrasse 9, 89075 Ulm, Germany

Y. Hodysh · W. Nowicky  
Ukrainian Anti-Cancer Institute,  
Margaretenstrasse 7, 1040 Vienna, Austria

**Abstract** *Background:* This monocentric study evaluated the effect of Ukrain in the treatment of pancreatic cancer. *Material and methods:* Between January 1996 and December 1999 we treated 21 patients with 10 mg Ukrain every second day  $\times 10$ . The control group received supportive treatment only. *Results:* Ukrain treatment was well tolerated. Mean values on pain measure and Karnofsky index were significantly better in the Ukrain group than in controls ( $P < 0.05$ ). One-year survival was 76% in the Ukrain group, compared to 9.5% in the control group. Median survival after treatment with Ukrain was 574 days, compared to 197 days in the control group.

*Conclusions:* Our data demonstrate

that Ukrain improves quality of life in patients suffering from advanced pancreatic cancer and significantly prolongs survival time in these patients.

**Keywords** Pancreatic cancer · Ukrain (NSC-631570) · Palliative surgery

### Introduction

Pancreatic cancer accounts for 2–3% of malignant tumors and is the sixth most common oncological disease and the fifth most common cause of cancer death, with an incidence of approx. 9 per 100,000 [1, 2]. It is a malignancy that causes late symptoms, and diagnosis is therefore late and cure rare. At the time of diagnosis most patients show progression of the disease beyond the pancreas, either through the direct invasion of neighboring structures or metastases in regional lymph nodes, liver, peritoneum, lungs, bones, or brain. Median survival time is approx. 4–6 months after diagnosis. Fewer than 10% of patients survive 1 year after diagnosis, and many suffer from increasingly severe pain, nausea and vomiting, anorexia, weight loss, and weakness as the disease progresses. Five-year survival in cases of early diagnosis

is 3.6% [3]. In the few cases in which early diagnosis is made, surgical pancreatico-duodenectomy may be attempted by those with skill and experience in performing this challenging operation. However, although operative mortality rates have much improved, surgery has only a slight effect on survival time. Adjuvant chemoradiation therapy has shown prolonged survival time in some trials but not in others [4].

Recent studies of chemotherapy for advanced pancreatic cancer have used gemcitabine, a novel nucleoside analogue. A phase II trial by Casper et al. [5] observed a partial response of 11%. A phase III study by Burris et al. [6] compared the effectiveness of gemcitabine and 5-fluorouracil (5-FU, NSC-19893) in patients with newly diagnosed advanced pancreatic carcinoma. Clinical benefit was measured by a combination of visual analogue scale, change in analgesic use, and improvement in

Karnofsky Performance Status. Clinical benefit response was experienced by 23.8% of gemcitabine-treated patients, compared to 4.8% of 5-FU treated patients.

Because of the harmful effects of chemotherapy on healthy cells, many physicians carefully consider its use in the case of pancreatic cancer. The rationale of its use is often more to slow the spread of metastases and to improve the quality of life than to inhibit growth of the main tumor. The effect of chemotherapy on survival in pancreatic cancer is negligible. Gemcitabine is now used as standard therapy for advanced pancreatic cancer, but unfortunately it prolongs median survival of patients by only 4–6 weeks. The study by Burris et al. [6] found the median survival time to be only 5.65 and 4.41 months in patients treated with gemcitabine and 5-FU, respectively; the 12-month survival rate was 18% in gemcitabine patients and 2% in 5-FU patients. Unfortunately, all patients had progressed within 14 months of starting therapy, and no patient survived beyond 19 months.

Ukrain (NSC-631570; Nowicky Pharma, Vienna, Austria) is a semisynthetic compound from alkaloids from *Chelidonium majus* L. and thiophosphoric acid triaziridide that is known to be an immune modulator [7]. It has demonstrated considerable promise in the treatment of a variety of oncological diseases [8, 9, 10, 11, 12]. It accumulates in cancer cells within minutes of administration, a property that can be seen due to its auto-fluorescence under UV light [13]. Although the exact mode of action of Ukrain is not yet known, it is destructive to cancer cells while leaving normal cells undamaged [14]. Ukrain develops its anticancer activity via a dose-related inhibition of DNA, RNA, and protein synthesis [12, 13]. This inhibition is limited to malignant cells [14, 15, 16]. The selective inhibition reflects the preferential uptake of Ukrain by tumor cells, as can be measured by monitoring the fluorescence of Ukrain within cells [16].

In vitro tests at the National Cancer Institute have shown Ukrain to be effective and malignocytolytic against all human cancer cell lines tested whereas 5-FU did not reduce tumor cell mass but only inhibited the growth of malignant cell lines [15]. Ukrain has been shown to induce apoptosis (programmed cell death) in malignant cells [16]. We previously conducted a study comparing Ukrain with 5-FU in colorectal cancer. The results in the Ukrain-treated group were much better than those in the 5-FU group, and the in vitro effectiveness of Ukrain in the cancer lines screening panel was much higher than that with 5-FU. Moreover, during 1995 we treated three pancreatic cancer patients with Ukrain at their own insistence, with surprisingly encouraging results. Standard treatment at our clinic at that time was chemotherapy combining 5-FU, doxorubicin, and mitomycin C, which had only a negligible effect on survival in pancreatic cancer patients. In the later study by Burris et al. [6] median survival of 5-FU treated patients was

only 4.41 months. Other studies have not demonstrated any advantage of combined chemotherapy regimens compared to 5-FU alone [17, 18, 19]. Many possible severe side effects of 5-FU therapy such as myelosuppression, ulceration of the gastrointestinal tract, cardiac ischemic episodes, and renal failure must be taken into consideration in patients already suffering from a severe disease.

Because of the unsatisfactory results of standard therapy and the encouraging results of Ukrain treatment we initiated this pilot study to investigate whether Ukrain would be effective in controlling the growth of pancreatic cancer and improving the quality of life for patients in late stages of this disease where prognosis is extremely poor.

## Patients and methods

### Patients

This controlled pilot study included 42 patients with pathologically diagnosed pancreatic cancer at the Department of General Surgery, National Medical University Kyiv, Ukraine between January 1996 and December 1999. None of the patients had adenocarcinoma of the distal bile duct, ampulla, or duodenum. Most had a tumor in the head of the pancreas, but two patients from the Ukrain group and four from the control group had pancreas body lesions. Most patients had pain at entry into the study. Patient characteristics are presented in Table 1.

After surgery, every patient was offered chemotherapy and was informed about the probable results of chemotherapy, and six patients decided for treatment with chemotherapy. Only patients who refused chemotherapy were proposed to enter the study. Forty patients were not amenable to surgical resection; reasons for unresectability were proximity to mesenteric vessels, adherence to retroperitoneum, positive peripancreatic lymph nodes, advanced age, and concomitant diseases. Two patients underwent pancreaticoduodenectomy. Patients received biliary or gastric bypasses when they had signs of biliary or gastric obstruction. Only two patients from the Ukrain group and three from the control group had no signs of biliary obstruction. Three patients from the Ukrain group and four from the control group had gastric obstruction and underwent gastric bypass.

### Patient assignment

The Pharmacological Committee from the Ministry of Health of Ukraine gave permission to conduct clinical studies with Ukrain in Ukraine. On the basis of this permission and other documentation the local ethics committee approved the study design. Signed informed consent was obtained from each patient before entry into the study. The 42 patients were randomly assigned to treatment with vitamin C plus Ukrain or vitamin C plus normal saline at the clinic before starting study therapy; eligibility was checked before randomization. Each patient drew a sealed envelope indicating the allocated treatment. Treatment allocation was summarized in a master randomization list. Nurses or physicians filled out the analgesic consumption forms. In addition, performance status was assessed.

Table I Characteristics of patients (percentages)

	Ukrain	Control
Age (years)		
Mean	60.7	65.4
Range	40-81	43-83
Sex		
Men	81	47.6
Women	19	52.4
Tumor stage (UICC 1997)		
II	4.8	9.5
III	23.8	23.8
IVA	38.1	42.9
IVB	33.3	23.8
Metastases		
Peritoneal	9.5	14.3
Liver	23.8 <sup>a</sup>	14.3
Other	4.8	0
Initial Karnofsky index		
80-90	9.5	33.3
60-70	61.9	61.9
40-50	19	4.8
Initial pain intensity <sup>b</sup>		
6-10	38.1	28.6
4, 5	47.6	57.1
2, 3	14.3	14.3
0, 1	0	0
Initial analgesic consumption <sup>c</sup>		
0-49	9.5	14.3
50-100	57.1	61.9
More than 100	33.3	23.8
Pancreatico-duodenectomy	4.8	4.8
Biliary bypass procedure		
Cholecho-jejunostomy	23.8	14.3
Hepatico-jejunostomy	52.4	57.1
Bypass procedure		
Gastric	4.8	4.8
Double	9.5	14.3
Alcoholization of the tumor and biopsy only	4.8	4.8

<sup>a</sup> Some patients had peritoneal and liver metastases

<sup>b</sup> Memorial visual analogue scale

<sup>c</sup> Milligrams of morphine equivalent

#### Treatment

Ukrain was supplied as a solution ready for injection. Vitamin C was used as solution for injection and as tablets. The Ukrain therapy cycle was defined as 10 mg intravenously,  $\times 10$ , every other day. A vitamin C cycle was defined as 3 g intravenously,  $\times 10$ , every other day, and 2.4 g oral divided into three doses on the same days. Patients in the Ukrain group received a Ukrain therapy cycle and a vitamin C therapy cycle on the same days. The control group received a vitamin C cycle and 10 ml intravenously normal saline on the same days. Vitamin C as a solution for injection, 3 g,

was diluted in normal saline, 200 ml, and administered as an intravenous infusion over 25 min. Then either 10 mg Ukrain or 10 ml normal saline (control group), was injected in the same vein line over 5 min. High doses of vitamin C were included in the treatment schedule of all study patients because we had earlier observed that high doses of vitamin C improve wound healing and prevent postoperative wound suppuration. Patients did not receive concomitant radiation therapy, chemotherapy, hormonal therapy, or corticosteroids during the study.

#### Efficacy and safety evaluation

In addition to survival as primary end-point of efficacy, other measures of therapeutic benefit were body weight change, Karnofsky performance status, and pain intensity. Hematological, immunological, and biochemical data were also considered. In some of patients computed tomography data showed response to therapy, but in most of patients ultrasound investigation was used. The principal efficacy end point in this study was overall survival, which was measured from the time of the first day of treatment until death or date of last follow-up. Survival was calculated using the log-rank test. Body weight was measured before and after the study therapy. Karnofsky Performance Status was measured before and after the study therapy. Pain intensity was assessed by analgesic consumption dose and analgesic consumption frequency; change in dose or frequency was taken as equivalent for change in pain intensity. Analgesic consumption was measured on a form filled out by the nurses and physicians (milligrams of morphine equivalent per day). Patients were evaluated by history and physical examinations, complete blood counts, chemistry, immunology profiles, and urinalyses. All signs, symptoms or laboratory abnormalities were assessed by WHO criteria for toxicities.

#### Results

One-year survival was 76% in the Ukrain group and 9.5% in the control group; 2-year survival was 48% in the Ukrain group and 5% in the control group (Fig. 1). Of 21 patients in the Ukrain group 3 were still alive on 5 January 2002, whereas all patients of the control group had died. Survival for the first patient was 2105 days (more than 5.5 years), for the second patient 1349 days (more than 3.5 years), and for third patient 1363 days (more 3.5 years). Three patients (14.3%) died within 5 months due to progression of the disease, and two died of other diseases (one each of myocardial infarction and heart failure) within 8 months. Six Ukrain patients (28.6%) but no patients from the control group put on weight (7% increase in body weight). Seventeen (81.0%) patients in the Ukrain group showed positive change in analgesic consumption. Median duration of response was 10 months in the Ukrain group. Four patients from the Ukrain group were completely free from pain and did not need analgesics. Two who are still alive do not complain of pain. Both pain and Karnofsky Performance Status improved in ten Ukrain patients. Three Ukrain patients had an improvement in pain and no worsening of Karnofsky Performance Status (Fig. 2). Three Ukrain patients (14.3%) achieved partial tumor response with median duration of 14 months, and nine patients (42.9%)

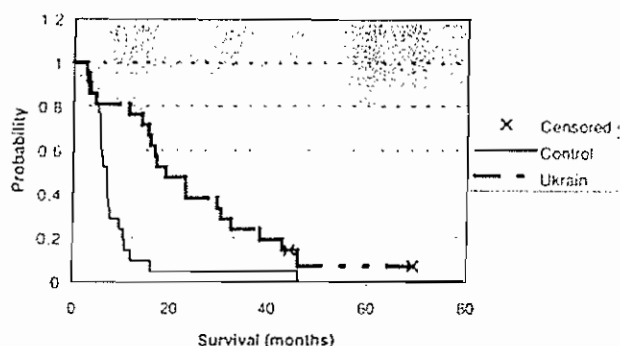


Fig. 1 Kaplan-Meier survival curves in pancreatic cancer patients ( $n=42$ )

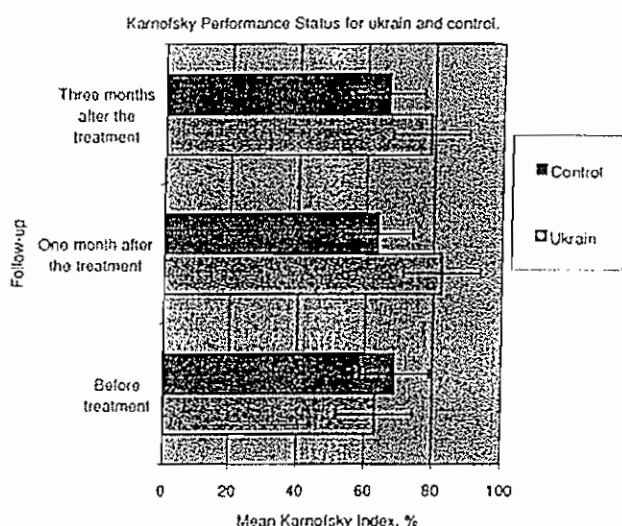


Fig. 2 Karnofsky Performance Status in Ukrain and control groups

had stable disease for 13 months (median value). Three patients (14.3%) from the control group had stable disease with median duration of 5 months; none achieved a complete or partial response.

Blood and urine examinations revealed no negative or toxic effect of Ukrain and moreover showed an improvement in the immune profile in Ukrain-treated patients (Table 2). Both treatment schemes were generally well tolerated. The typical reaction in Ukrain patients was a temperature increase of  $1-1.5^{\circ}$  which appeared 3-5 h after injection, and which disappeared without use of medication. Temperature increase was observed in those patients who showed partial tumor response (three patients) or stable diseases (seven patients). Usually after the third to fifth injection of Ukrain patients described an improvement in the general condition, with increased appetite and normalization of sleep and decreased local pain.

Table 2 WHO grade toxicity in Ukrain-treated patients (percentages)

	WHO grade				
	0	1	2	3	4
Segmented neutrophils	76.2	23.8	0	0	0
White blood cells	81.0	19.0	0	0	0
Hemoglobin	95.2	4.8	0	0	0
Aspartate transaminase	71.4	23.8	4.8	0	0
Alanine transaminase	66.7	23.8	9.5	0	0
Nausea/vomiting	90.5	4.8	4.8	0	0
Diarrhea	85.7	14.3	0	0	0
Constipation	90.5	9.5	0	0	0
State of consciousness	95.2	4.8	0	0	0
Pain	90.5	9.5	0	0	0
Allergic reactions	100.0	0	0	0	0

Within 2-3 min after the Ukrain injection some patients noted a short-term increase in pain intensity, weakness, itching, and paresthesia in the upper abdomen. These reactions declined without additional treatment. We believe that these reactions were caused by tumor degradation products due to the Ukrain action. However, during treatment with Ukrain we did not observe such symptoms of chemotherapy-related toxicity as neutropenia, anemia, vomiting, or hair loss. There was no allergic reaction in any Ukrain-treated patient.

## Discussion

The prognosis in patients with advanced pancreatic cancer is extremely poor. Improving their prognosis requires effective therapy. We designed this controlled pilot study to investigate whether Ukrain prolongs survival or at least lessens disease-related suffering. Gemcitabine was not approved in Ukraine when the study started. The available chemotherapy has shown only a negligible effect on the survival of pancreatic cancer patients, while their quality of life has deteriorated. Therefore it was usual practice to treat advanced pancreatic cancer patients with symptomatic surgery and high doses of vitamin C.

Ukrain revealed a cytotoxic and cytolytic effect on cancer cell lines in vitro. We had conducted a previous study in colorectal cancer comparing Ukrain with 5-FU. The results in the Ukrain-treated group were much better than those in the 5-FU group. In addition, the in vitro effectiveness of Ukrain in the cancer lines screening panel was much higher than that of 5-FU. Moreover, until the start of the pilot study we had treated three pancreatic cancer patients with Ukrain at their own insistence, with encouraging results. These were the reasons for us to conduct a study with Ukrain in pancreatic cancer and for the local ethics committee to approve the study.

Survival in the Ukrain group was surprisingly high (Fig. 2); 12-month survival was 76%, compared to 9.5%

in the control group. We observed a decrease in pain intensity in most Ukrain patients, usually from 10–15 days after the start of treatment. At the start of therapy patients had a short-term (2–3 h) increase in pain intensity in the primary tumor region and at the metastasis sites. In our opinion, these data can be explained by the accumulation of the drug in the tumor tissue and its anticancer effect. Four patients from the Ukrain group became completely free from pain. Two of them who are still alive do not complain of pain.

Gemcitabine is now standard therapy in advanced pancreatic cancer. Our experience with Ukrain in pancreatic cancer includes the treatment of 73 patients until January 2002: 21 in the pilot study, 3 before, and 49 after the study. This experience allows comparison with a gemcitabine-treated control group from the study by Burris et al. [6]. Unfortunately, gemcitabine prolongs survival of patients only by 4–6 weeks more than 5-FU. In the study by Burris et al. the median survival duration was only 5.65 and 4.41 months in patients treated with gemcitabine and 5-FU, respectively. The 12-month survival rate was 18% in gemcitabine patients and 2% in 5-FU patients, and there were no survivors beyond 19 months after starting gemcitabine therapy, whereas in our study 12-month survival in the Ukrain group was 76%, and 36-month survival was 23.8%. Gansauge et al. [20] published results of treatment of 90 patients with unresectable pancreatic cancer. Patients in arm A received 1000 mg gemcitab-

ine/m<sup>2</sup>, those in arm B received 20 mg NSC-631570, and those in arm C received 1000 mg gemcitabine/m<sup>2</sup> followed by 20 mg NSC-631570 weekly. Median survival according to Kaplan-Meier analysis was 5.2 months in arm A, 7.9 months in arm B, and 10.4 months in arm C. Actuarial survival rates after 6 months were 26%, 65%, and 74% in arms A, B, and C, respectively.

The optimum schedule for Ukrain therapy in pancreatic cancer with regard to dose and number of therapy cycles has not yet been defined. Further efforts should focus on evaluating Ukrain in patients with an earlier stage of disease and combining it with other treatment modalities, for example, neoadjuvant Ukrain therapy aiming at tumor encapsulation and resectability improvement with subsequent adjuvant therapy. Additional studies are required to evaluate whether more than two Ukrain therapy cycles would further prolong survival in pancreatic cancer patients. Future studies should be conducted with three or four therapy cycles to define an optimum treatment schedule. Our results with Ukrain in the treatment of advanced pancreatic cancer are promising with regard to improving quality of life and lengthening patients' survival. However, these data must be confirmed by further trials.

**Acknowledgements** We thank Prof. Dr. Frank Gansauge, University of Ulm, Germany for helpful discussion and reading the manuscript.

## References

- Seeber S, Schütte J (1995) *The-rapiekonzepte Onkologie*. Springer, Berlin Heidelberg New York
- Fischer DS, Tish Knobf M, Durivage HJ (1997) *The cancer chemotherapy handbook*. Mosby, St Louis
- Scnall SF, Macdonalds JS (1996) Chemotherapy of adenocarcinoma of the pancreas. *Semin Oncol* 23:220–228
- Alter CL (1996) Palliative and supportive care of patients with pancreas cancer. *Semin Oncol* 23:229–240
- Casper ES, Green MR, Kelsen DP, et al (1994) Phase II trial of gemcitabine (2',2'-difluorodeoxycytidine) in patients with adenocarcinoma of the pancreas. *Invest New Drugs* 12:29–34
- Burris HA, Moore MJ, Andersen J, et al (1997) Improvements in survival and clinical benefit with gemcitabine as first-line therapy for patients with advanced pancreas cancer: a randomized trial. *J Clin Oncol* 15:2403–2413
- Liepins A, Nowicky JW (1992) Activation of spleen cell lytic activity by the alkaloid thiophosphoric acid derivative: Ukrain. *Int J Immunopharmacol* 14:8:1437
- Vatanasapt V, Wongpratoom W, Mairiang P, Mairiang E, Chaiyakam C, Buddhisawasd V, Pairojkul C, Nowicky JW (1991) Preliminary report on clinical experience in the use of Ukrain. *Thai Cancer J* 17:20
- Musianowycz J, Judmajer F, Manfreda D, Spängler P, Albrecht H, Hoffmann J, Meijer D (1992) Clinical studies of Ukrain in terminal cancer patients (phase II). *Drugs Exp Clin Res* 18:45
- Staniszewski A, Slesak B, Kolodziej J, Harlozinska-Smyrka A, Nowicky JW (1992) Lymphocyte subsets in patients with lung cancer treated with thiophosphoric acid alkaloid derivatives from *Chelidonium majus* L (Ukrain). *Drugs Exp Clin Res* 18:63
- Bondar G, Borota A, Yakovets Y, Zolotukhin S (1998) Comparative evaluation of the complex treatment of rectal cancer patients (chemotherapy and X-ray therapy, Ukrain monotherapy). *Drugs Exp Clin Res* 24:5–6
- Uglyanitsa K, Nefyodov L, Nowicky JW, Brzosko W (1998) The effect of Ukrain on cancer of the urinary bladder. 17th International Cancer Congress, Rio de Janeiro, 24–28 August
- Nowicky JW, Greif M, Hamler F, Hiesmayr W, Staub W (1988) Macroscopic UV-marking through affinity. *J Tumor Marker Oncol* 33:4
- Liepins A, Nowicky JW (1991) Ukrain is selectively cytostatic and/or cytotoxic to human tumor and HIV-infected cells but not to normal human cells. In: *Recent Advances in Chemotherapy*, Anticancer Section, Proceedings of the 17th International Congress of Chemotherapy, Berlin
- Nowicky JW, Hiesmayr W, Nowicky W, Liepins A (1996) Influence of Ukrain on human xenografts in vitro. *Drugs Exp Clin Res* 22 [Suppl]

16. Liepins A, Nowicky JW, Bustamante JO, Lam E (1996) Induction of bimodal programmed cell death in malignant cells by the derivative Ukrain (NSC-631570). *Drugs Exp Clin Res* 22 [Suppl]
17. Kolshelnick Y, Moskvina E, Binder BR, Nowicky JW (1998) Ukrain (NSC-631570) inhibits angiogenic differentiation of human endothelial cells in vitro. Abstracts, 17th International Cancer Congress (Brazil), pp 91-95
18. Sulkowski U, Buchler M, Pederzoli P, Arnold R, Dinse P, Kay A, Haus U, Beger G (1999) A phase II study of high-dose octreotide in patients with unresectable pancreatic carcinoma. *Eur J Cancer* 35:1805-1808
19. David AK, Vaughn DJ, Holroyde CP, Armstead B, Haller DG (2000) A phase II trial of 5-fluorouracil, leucovorin, and interferon alpha 2A (IFN-alpha 2a) in metastatic pancreatic carcinoma: a Penn Cancer Clinical Trials Group (PCCTG) trial. *Am J Clin Oncol* 23:37-39
20. Gansauge F, Ramadani M, Pressmar J, Gansauge S, Muehling B, Stecker K, Cammerer G, Leder G, Beger HG (2002) NSC-631570 (Ukrain) in the palliative treatment of pancreatic cancer. Results of a phase II trial. *Langenbecks Arch Surg* 386:570-574

## COMPARISON OF CHEMOTHERAPY AND X-RAY THERAPY WITH UKRAIN MONOTHERAPY FOR COLORECTAL CANCER

SUSAK Y.M.<sup>1</sup>, ZEMSKOV V.S.<sup>1\*</sup>, YAREMCHUK O.Y.<sup>1</sup>, KRAVCHENCO O.B.<sup>1</sup>, YATSYK I.M.<sup>1</sup>, KORSH O.B.<sup>2</sup>

- 1) Department of General Surgery and Department of Oncology, Ukrainian State Medical University, Gorkogo St. 150-15, Kiev, Ukraine.  
2) Ukrainian Anti-Cancer Institute, Margaretenstrasse 7, 1040 Vienna, Austria.

**Summary:** Ninety six colorectal carcinoma patients were included in a randomised study. 48 were treated with Ukrain monotherapy (15 with metastatic and 33 with nonmetastatic colorectal carcinoma) and 48 with 5-fluorouracil (5-FU) and X-ray therapy (the same randomised groups). The results of therapy including clinical, haematological, immunological and biochemical parameters show that Ukrain has favourable properties in the treatment of colon and rectal cancer as a monotherapy because of its malignotoxic and immunomodulating action. Objective response rate in the group of metastatic colorectal cancer treated by Ukrain was 40%. There was no registered tumour regression in the group treated by 5-FU. Operability is strongly facilitated by pretreatment with Ukrain. The survival rate (up to 21 months) in the Ukrain-treated patients with nonmetastatic colorectal cancer was 78.6% and 33.3% in a corresponding control group. Ukrain is a new effective drug in the therapy of colorectal cancer. It can be useful both for the therapy of metastatic colorectal cancer and for neoadjuvant therapy of nonmetastatic colorectal cancer.

### Introduction

Ukraine is chemically a Chelidonium thiophosphoric acid derivative: Tris[2-[[5bS-(5ba,6b,12ba)]-5b,6,7,12b,13,14-hexahydro-13-methyl[1,3]benzodioxolo[5,6-c]-1,3-dioxolo[4,5-i]phenanthridinjum-6-ol]-ethaneaminy]phosphine-sulfide 6HCl. (Patent No. 4.970.212. USA, 1990). (Fig. 1)

High toxicity and unsatisfactory results of 5-fluorouracil require further investigation to find new agents for colorectal cancer treatment (1, 2).

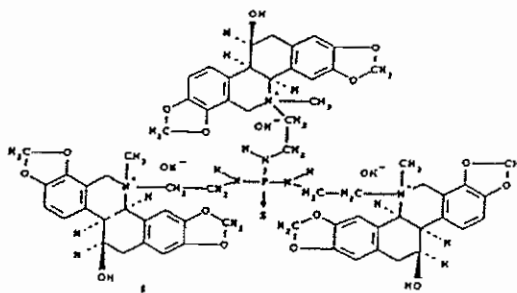


Fig. 1 Formula of Ukrain.

\* Author to whom correspondence should be addressed.



Table I TNM and Dukes' Staging in colon carcinoma

	Patient group Ukrain			Patient group 5-Fluorouracil		
	TNM-Staging	Dukes'	No. of pts.	TNM-Staging	Dukes'	No. of pts.
1. Cancer of rectum	T <sub>1</sub> N <sub>0</sub> M <sub>0</sub>	a	1	T <sub>1</sub> N <sub>0</sub> M <sub>0</sub>	a	1
	T <sub>2</sub> N <sub>1</sub> M <sub>0</sub>	a	4	T <sub>2</sub> N <sub>1</sub> M <sub>0</sub>	a	2
	T <sub>2</sub> N <sub>0</sub> M <sub>0</sub>	b <sub>1</sub>	2	T <sub>2</sub> N <sub>0</sub> M <sub>0</sub>	b <sub>1</sub>	3
	T <sub>2</sub> N <sub>1</sub> M <sub>0</sub>	b <sub>1</sub>	4	T <sub>2</sub> N <sub>1</sub> M <sub>0</sub>	b <sub>1</sub>	3
	T <sub>3</sub> N <sub>0</sub> M <sub>0</sub>	b <sub>2</sub>	4	T <sub>3</sub> N <sub>0</sub> M <sub>0</sub>	b <sub>2</sub>	3
	T <sub>4</sub> N <sub>0</sub> M <sub>0</sub>	b <sub>2</sub>	4	T <sub>4</sub> N <sub>0</sub> M <sub>0</sub>	b <sub>2</sub>	2
	T <sub>3</sub> N <sub>1</sub> M <sub>1</sub> hep	c	4	T <sub>4</sub> N <sub>1</sub> M <sub>0</sub>	c	2
	T <sub>4</sub> N <sub>1</sub> M <sub>x</sub>	c	1	T <sub>4</sub> N <sub>1</sub> M <sub>0</sub>	c	1
	T <sub>2</sub> N <sub>3</sub> M <sub>1</sub> hep	c	2	T <sub>3</sub> N <sub>1</sub> M <sub>1</sub> hep	c	4
				T <sub>4</sub> N <sub>1</sub> M <sub>x</sub>	c	1
			T <sub>4</sub> N <sub>3</sub> M <sub>1</sub> hep	c	2	
2. Cancer of sigmoid	T <sub>2</sub> N <sub>0</sub> M <sub>0</sub>	a	1	T <sub>1</sub> N <sub>0</sub> M <sub>0</sub>	a	1
	T <sub>3</sub> N <sub>0</sub> M <sub>0</sub>	b <sub>1</sub>	3	T <sub>2</sub> N <sub>0</sub> M <sub>0</sub>	a	1
	T <sub>3</sub> N <sub>1</sub> M <sub>0</sub>	c	2	T <sub>3</sub> N <sub>0</sub> M <sub>0</sub>	b <sub>1</sub>	4
	T <sub>4</sub> N <sub>1</sub> M <sub>0</sub>	c	2	T <sub>3</sub> N <sub>1</sub> M <sub>0</sub>	c	1
	T <sub>4</sub> N <sub>1</sub> M <sub>1</sub> hep	c	2	T <sub>4</sub> N <sub>1</sub> M <sub>0</sub>	c	2
				T <sub>4</sub> N <sub>1</sub> M <sub>1</sub> hep	c	1
			T <sub>4</sub> N <sub>1</sub> M <sub>1</sub> hep	c	1	
3. Cancer of ascending colon	T <sub>3</sub> N <sub>0</sub> M <sub>0</sub>	b <sub>2</sub>	2	T <sub>3</sub> N <sub>0</sub> M <sub>0</sub>	b <sub>2</sub>	1
	T <sub>3</sub> N <sub>1</sub> M <sub>1</sub> hep	c	1	T <sub>3</sub> N <sub>1</sub> M <sub>1</sub> hep	c	1
	T <sub>4</sub> N <sub>3</sub> M <sub>1</sub> hep	c	2	T <sub>4</sub> N <sub>3</sub> M <sub>1</sub> hep	c	3
	T <sub>4</sub> N <sub>3</sub> M <sub>1</sub> hep	c	1			
	pancreas					
4. Cancer of caecum	T <sub>3</sub> N <sub>0</sub> M <sub>0</sub>	b <sub>2</sub>	2	T <sub>2</sub> N <sub>1</sub> M <sub>0</sub>	a	1
	T <sub>4</sub> N <sub>1</sub> M <sub>0</sub>	b <sub>2</sub>	2	T <sub>3</sub> N <sub>0</sub> M <sub>0</sub>	b <sub>2</sub>	3
	T <sub>4</sub> N <sub>1</sub> M <sub>1</sub> hep	c	2	T <sub>4</sub> N <sub>1</sub> M <sub>0</sub>	b <sub>2</sub>	2
			48	T <sub>4</sub> N <sub>1</sub> M <sub>1</sub> hep	c	2
						48

New properties of Ukrain are broadly shown (3-8) with special immunological activities *in vitro*, *in vivo* and clinically (9-13). The malignotoxic properties of Ukrain were evaluated on different cancer cell culture lines (EORTC, European Organisation of Research and Treatment of Cancer, The Netherlands: E90/029, W122, UKRS-222; NSC B238865; National Cancer Institute, Bethesda, Maryland, USA NSC: 63 1570-W/1) (14, 15). It was shown that Ukrain increased macrophage tumoricidal activity in murine adenocarcinomas (16).

Published results from the National Cancer Institute, Bethesda, Maryland, USA (17) showed that Ukrain (NSC 63 1570) had a more than 10C-

fold higher cytotoxic activity on human colon carcinoma cell culture lines (Colo 205, DLD-1, HCC-2998, HCT-116, HT29, KM12, KM20L2, SW620) than the traditionally broadly-used 5-fluorouracil (NSC 19893). In the EORTC study Ukrain was toxic to the colorectal cell line CXF. It was the aim of this study to show whether there is a correlation of the *in vitro* effects of Ukrain to clinical experience, and to evaluate the usefulness of Ukrain as a new drug in the treatment of colorectal cancer.

The toxic and immunosuppressive influence of cytostatic agents has adverse effects on homeostasis in colon cancer patients. Oncological therapy would require maximal toxicity against tumour cells and minimal toxicity to the organism

with improvement of the immune system. This is one of the properties of Ukrain (18-21).

The aim of this controlled clinical study was to compare the results of four groups of patients with colorectal carcinomas treated with Ukrain or 5-FU and to find new therapeutic possibilities for these severe diseases.

#### Patients and methods

96 patients (48 male) with colorectal carcinomas were included in this controlled clinical study (Table I). Their average age was 59.7 years. All tumours were histologically verified as adenocarcinomas of various degrees of differentiation (staging according to Table I after the Tumour node metastasis (TNM) classification). All patients were informed about the therapeutic properties of the preparation and advised that they might stop treatment at any time. They gave their written agreement for the therapy after the Ethic Commission approved the study. The study was performed in accordance with the Declaration of Helsinki (1964), revised in Tokyo (1975), with subsequent Venice (1983) and Hong Kong (1989) amendments. Randomisation was carried out using a computer programme. The study protocols were accepted by the Arzneimittelbeirat at the Bundesministerium für Gesundheit, Sport und Konsumentenschutz, Austria and the Ethic Commission of Kiev Medical University Clinic.

There were four randomised groups:

- 1) metastatic colorectal cancer patients treated with Ukrain (15 patients);
- 2) non-metastatic colorectal cancer patients treated with Ukrain (33 patients);
- 3) metastatic colorectal cancer patients treated with 5-FU (15 patients) (1st control group);
- 4) non-metastatic colorectal cancer patients treated with 5-FU (33 patients) (2nd control group).

In the 1st Ukrain-treated group of 15 patients with metastatic colorectal cancer, palliative operation was performed in 12 cases. In the 2nd Ukrain-treated group of 33 patients, radical surgery was performed in 25 cases, palliative sur-

gery in 3 cases and 5 patients were treated without operation. Ukrain-treated groups received 10 injections of 10 mg (two ampoules of 5 mg each) Ukrain every second day, i.v., total dose: 100 mg. The first course of Ukrain was performed before operation, followed by an interval of 10 days, and then the identical course was repeated. Neither chemotherapy nor X-ray therapy was performed before or during treatment with Ukrain.

In the 1st control group of 15 metastatic colorectal cancer patients, palliative surgery was performed in 7 cases; two patients received X-ray therapy. In the 2nd control group of 33 patients, radical surgery was performed in 23 cases, palliative surgery in 4 cases and 6 patients were treated without operation. Eleven patients received X-ray therapy. The control groups received two courses 5-FU 600 mg/m<sup>2</sup> every second day, injected i.v. together with salt solution (400 ml) to a total amount of 5.5-6.0 g. The first course of 5-FU was before surgery and the second course after surgery. The symptomatic therapy was the same for both groups. The Karnofsky index was between 50 and 90% for all patients.

The therapeutic effect was evaluated by comparison of the results of the investigations made before and after the therapies, including clinical control and different haematological, immunological and biochemical parameters, endoscopic and ultrasound examinations, and assessment of common and specific reactions after application of the drugs.

The following methods were used to evaluate the parameters: lymphocyte subsets were defined with IKO-31 (CD-8) for T-suppressors (16), IKO-86 (CD-4) for T-helpers (Moscow Oncological Centre). The activity of killer cells was determined with <sup>3</sup>H-uridine (22). Immunoglobulins A, M and G were found in human sera by radioimmunodiffusion. The phagocytic activity was determined microscopically by evaluating the phagocytic activity of neutrophils on staphylococci. The phagocytic index was the average number of bacteria lysed by one neutrophilic cell. Pathomorphological studies of tumour biopsies were carried out on patients before and after treatment with Ukrain and with 5-FU. The survival rate was

measured from the date of randomisation to death or to the date of last communication.

The criteria for treatment toxicity were defined by the World Health Organization (23).

## Results

Group 1 patients with metastatic colorectal cancer, who had received Ukrain, showed after 5-6 injections in all cases (100%) from day 10 to 12 improvement of their general condition, decreased toxic signs, decreased fatigue and vomiting, reappearance of appetite, reduced subfebrility and improvement of sleep. Ten patients (66.7%) after treatment noticed a local effect such as decreased rectal bleeding, improvement of faecal movement and decreased local pain. Colostomy was postponed in five patients. After two courses of Ukrain treatment, the Karnofsky index increased from 60.7 to 72.9. Tumour nodes became softer and more movable. Objective decrease in the size of primary tumours or liver metastases in metastatic colorectal cancer after Ukrain treatment was noticed in 6 of 15 cases (response rate 40%). Of the four metastatic colorectal carcinoma patients started on Ukrain therapy in 1993, three had duration-of-life over 15 months and one patient is still alive after two years.

Group 2 Ukrain-treated patients with colorectal cancer showed in 30 cases (90.9%) notable improvement of general condition; in 13 cases (39.3%) there was a positive local effect, with decreased local pain; tenesmus and rectal bleeding stopped. Resectability was achieved in eight patients. No metastases were seen during operation. Decrease of bleeding from tumour tissue at mechanic contact and absence of ulceration were noted. After two courses of Ukrain treatment the Karnofsky index increased from 70.6 to 79.4. Of 14 patients in the second group treated by Ukrain in 1992-1993, 11 (78.6%) are still alive; two of them were not operated and nine had radical surgery. Only one patient has died from those operated radically.

In both Ukrain-treated groups, toxicity was 0 according to WHO criteria. No general or local

negative responses (including allergic reactions) to administration of the preparation were reported. Three patients had an increase in body temperature up to 38°C during the first three injections but afterwards the temperature returned to normal.

Patients in the 1st control group with metastatic colorectal cancer showed after 5-FU therapy subjective deterioration in general condition in 14 cases (93.3%). We observed worsening of the general status, appetite, sleep and appearance of fatigue. Intoxication signs in these patients increased: nausea (toxicity 2), lethargy (toxicity 2), cardiac dysrhythmia (toxicity 1), and hand-foot syndrome (according to WHO criteria). The Karnofsky index decreased from 63.6 to 55.0 after courses of 5-FU therapy. Improvement of the local status (decrease of local pain and cessation of rectal bleeding) was observed in only one case (6.7%) in a patient receiving X-ray therapy. Objective regression of primary tumour or metastases was not observed. From the three patients treated by 5-FU in 1993, no one lived more than 11 months. In 12 cases (80%) we observed hepatotoxic or nephrotoxic effects of 5-FU and in five cases chemotherapy was stopped because of an increase of hepatotoxic effects manifested in two to three-fold increases in transaminase activity and an increase in bilirubin level above normal. Nephrotoxic effects were revealed by the appearance of protein in the urine and a rise of creatinine by more than 20%.

Patients in the 2nd control group of colorectal cancer showed a deterioration in their general condition in 29 cases (87.9%). Local effect was registered in only three cases (9.1%) receiving X-ray therapy. The Karnofsky index decreased from 70.3 to 65.6 after 5-FU therapy. Hepato-, nephro- and neurotoxicity were observed in 20 cases (60.6%); in three cases there was only one course of 5-FU because of toxicity. Of the 15 patients treated by 5-FU in 1992-1993, after the 21-months observation period five are still alive (33.3%); in three cases there was radical surgery and in two cases palliative surgery. Of 10 patients with fatal outcome, five were operated radically.

The median values of the haematological, bio-

Table II Median values of haematological, biochemical and immunological parameters

		UKRAIN Therapy		Control: FU Therapy	
		before	after	before	after
erythrocytes	10 <sup>6</sup> /mm <sup>3</sup>	4.01±0.22	4.02±0.24	3.98±0.26	3.31±0.24
leukocytes	10 <sup>9</sup> /mm <sup>3</sup>	9.62±1.42	9.02±1.7	9.53±0.99	8.66±0.99
lymphocytes		23.80±4.09	29.78±4.15	24.47±2.86	17.12±2.11
rod-shaped		12.23±4.9	9.38±4.6	11.37±2.44	13.87±3.84
segmented		55.35±3.7	53.76±3.6	56.31±2.31	58.55±2.89
eosinophils		3.41±0.71	4.23±0.96	3.54±1.11	2.82±1.02
monocytes		6.22±1.01	5.43±1.12	5.98±1.09	6.21±1.16
l per. lymph.		1.52±0.29	3.63±0.24	1.62±0.21	1.08±0.20
T-lymphocytes		39.8±2.87	45.89±3.45	39.28±3.37	34.31±3.23
B-lymphocytes		8.67±1.47	10.64±2.98	9.34±1.43	7.46±1.38
T-helper		29.04±2.67	31.64±1.65	30.32±2.11	24.08±1.11
T-suppressor		30.04±1.45	23.88±1.55	30.12±2.8	27.43±3.09
H/S ratio		0.97±0.07	1.32±0.11	1.01±0.12	0.88±0.14
granular lymphs.	%	1.49±0.11	3.47±0.28	1.67±0.27	1.05±0.22
NC-activity		25.43±3.33	37.96±4.12	24.98±3.02	27.7±4.53
phag. activity		86.61±1.33	99.72±2.05	86.46±1.84	89.16±2.65
phag. index		9.42±1.22	14.06±1.34	9.87±1.30	9.46±1.06
SGOT	U/l	0.29±0.08	0.21±0.03	0.33±0.07	0.92±0.4
SGPT	U/l	0.35±0.06	0.30±0.04	0.33±0.08	0.56±0.3
IgA	mcg/ml	2.88±1.12	4.07±1.02	2.91±0.62	3.01±0.56
IgM	mcg/ml	0.72±0.11	0.85±0.12	0.78±0.11	0.98±0.24
IgG	mcg/ml	12.23±1.42	18.54±2.21	11.98±1.66	14.84±1.74
CIK	ng/ml	271.84±17.3	202.33±15.82	287.41±20.2	305.43±21.8
interferon	IU	15.3±1.8	21.8±2.0	15.9±2.6	10.7±2.3
proteins	g/dl	75.21±1.66	74.54±2.05	74.48±3.81	69.72±2.55
bilirubin	mg/dl	18.39±3.22	17.92±2.96	18.67±4.43	22.39±2.88
sodium	m val	142.5±5.22	136.8±7.88	142.3±4.96	133.8±6.42
potassium	m val	4.15±0.42	4.21±0.91	4.17±0.56	3.98±0.76

chemical and immunological parameters are shown in Table II. Positive changes in the Ukrain treated group were recognised in the following parameters:

1. Increase in lymphocytes, B-lymphocytes.
2. Decrease in erythrocyte sedimentation rate.
3. Tendency to increase of T-lymphocytes (Fig. 2); increase of T-helpers (Fig. 3).
4. Increase in killer cell activity (Fig. 4).
5. Increase in phagocytic activity and phagocytic index.
6. Normalization of the H/S ratio.
7. Increase in IgG.

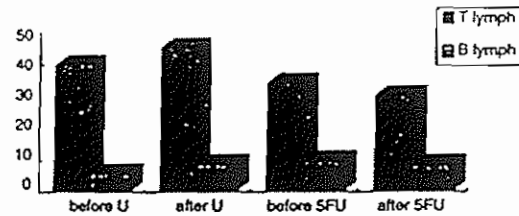


Fig. 2 Evaluation of T- and B-lymphocytes.




Fig. 3 Evaluation of T-helper and T-suppressor cells.

8. Decrease in circulating immune complexes.
9. Increase in large granular lymphocytes (Fig. 5).
10. Increase in peripheral blood lymphocytes (Fig. 6).

11. No negative changes in biochemical status.

Histological examination of tumour areas from biopsies showed a relative decrease of the adenocarcinoma mass, but an increase of tumour necrosis. Invading lymphocytes were found. Some cases showed sclerosis of the stroma of adenocarcinoma. Production of mature collagen was seen in the stroma of one case of rectal cancer. Necroses appeared in perivascular areas. Proliferation and development of metastases during the intervals between biopsies were not noticed.

The control group with 5-fluorouracil therapy showed in blood examinations:

1. Tendency to decrease in erythrocytes and lymphocytes.
2. Decrease in the immunological parameters.
3. Increase of the circulating immune complexes.
4. Decrease of the H/S ratio.
5. Tendency to decrease of the large granulated

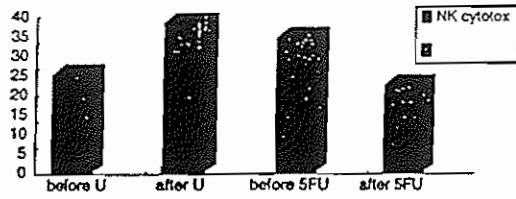


Fig. 4 Evaluation of natural killer (NK) cytotoxicity.




Fig. 5 Evaluation of large granular lymphocytes (LGL).

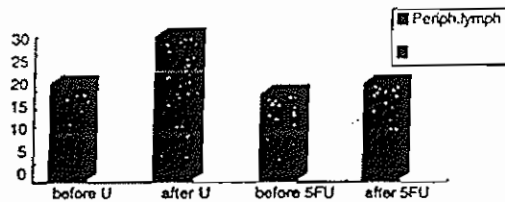


Fig. 6 Evaluation of peripheral blood lymphocytes.

lymphocytes.

No positive changes in blood parameters and immunograms were observed in patients from the control groups.

The groups treated with Ukrain showed less bleeding during endoscopic procedures than the control groups. No wounds were seen after biopsy in Ukrain-treated patients in contrast to the control groups.

Discussion

Results of treatment with 5-FU in our control group do not appear to differ from results in other clinical reports. Combination of 5-FU with interfe-

ron-alpha-2b for treatment of colorectal cancer has not been shown to be more effective (2, 24-26). No synergistic activity exists between the combination of 5-FU and alpha-interferon (24).

The present controlled clinical study shows clearly the major effects, atotoxicity and tolerability of Ukrain in patients with colon carcinomas when compared with the traditional cytostatic therapy with 5-FU. The immunostimulating properties connected with the cancerostatic properties of Ukrain allow an improvement of the general status of advanced colorectal cancer patients whose other possible therapy modalities had already been exhausted. The most important result achieved by treatment with Ukrain was the possibility of changing an inoperable status to operability and resectability of tumours.

In respect to parameters of colorectal carcinoma patients before and after treatment with Ukrain or 5-fluorouracil our studies clearly show advantages of therapy with Ukrain, in contrast to 5-FU therapy, for all randomised groups. The objective response-rate in the group of metastatic colorectal cancers treated with Ukrain was 40%, while there was no tumour regression in the group treated with 5-FU. We observed improvement of general status, decrease of fatigue, restoration of appetite, decrease of toxic signs (10-12 days from start of treatment) in patients treated with Ukrain in 90.9-100% of cases. In patients of the control groups who received generally accepted therapy including 5-FU, we observed worsening of the general status, appetite and sleep, together with appearance of fatigue, in 87.9-93.3%. Local improvement was registered in 39.3-66.7% cases under Ukrain therapy and in 6.7-9.1% of 5-FU-treated patients only if they had concomitant X-ray therapy. In the group treated with Ukrain we observed disappearance of toxic signs: nausea, lethargy, cardiac dysrhythmia, with a toxicity of 0 according to WHO criteria. In the control group increased signs were observed: nausea (toxicity 2), lethargy (toxicity 2), cardiac dysrhythmia (toxicity 1) and hand-foot syndrome, according to WHO criteria.

The survival rate up to 21 months in the Ukrain group was 78.6%; in the corresponding control group it was 33.3%. The survival rate was analy-

sed from 14-15 patients in the 2nd and 4th groups from the years 1992-1993. The remaining 69 patients started their treatment only in 1994, so too short a time has elapsed for evaluation of the results, which is reasonable only after 12 months. For this reason these cases are not included in the survival rate control. Their results will be published later.

We have no doubt that Ukrain is a necessary component in treatment modalities of colorectal carcinomas. This study has shown that the high sensibility of human colorectal cancer in the clinic corresponds to the *in vitro* results of colon cancer cell lines (17). These results indicate the broad introduction of Ukrain in the treatment of human colorectal cancer.

#### Conclusion

This study shows the many advantages of Ukrain therapy, compared with standard therapies, in patients with colorectal cancer. Ukrain reduces the primary tumour and metastases in 40% of metastatic colorectal cancer patients and can be useful in these cases. With preoperative and postoperative application of Ukrain, the results of the treatment were improved so that we can recommend Ukrain for neoadjuvant therapy of colorectal cancer.

#### References

- (1) Nichols P.H. et al. *Peri-operative modulation of cellular immunization in patients with colorectal cancer*. Clin. Exp. Immunol., 94, 4, 1993.
- (2) Punt C.J. et al. *Continuous infusion of high-dose 5-fluorouracil in combination with leucovorin and recombinant interferon-alpha-2b in patients with advanced colorectal cancer. A Multicenter Phase 2 study*. Cancer, 72, 2107, 1993.
- (3) Chłopkiewicz B., Marczevska J., Ejchart A., Anusewska E., Kozłowska J. *Evaluation of mutagenic, genotoxic and transforming properties of Ukrain*. Drugs Exptl. Clin. Res., XVIII (Suppl.), 31-34, 1992.
- (4) Juskiewicz T., Minta M., Włodarczyk B., Biernacki B. *Teratological evaluation of Ukrain in hamsters and rats*. Drugs Exptl. Clin. Res., XVIII (Suppl.), 23-29, 1992.
- (5) Kleinrok Z., Jagiello-Wojtowicz E., Matuszek B., Chodkowska A. *Basic central pharmacological properties of thiophosphoric acid alkaloid derivatives from Chelidonium Majus*. L. Pol. J. Pharmacol. Pharm., 44, 227, 1992.
- (6) Kleinrok Z., Jagiello-Wojtowicz E., Nowicky J.W., Chodkowska A., Fekdo M., Matuszek B. *Some pharmacological properties of prolonged administration of Ukrain in rodents*. Drugs Exptl. Clin. Res., XVIII (Suppl.), 93-96, 1992.
- (7) Remiszewska M., Wutkiewicz M., Jastrzebski Z., Czyżewska-Szafran H., Danysz A. *Pharmacological effects of Ukrain in rats and rabbits*. Acta Pol. Pharm., 49,43, 1992.
- (8) Wyczolkowska J., Czurwaj M., Maslinski C. *The immunomodulating preparation Ukrain does not induce anaphylactic sensitization in mice and guinea pigs*. Drugs Exptl. Clin. Res., XVIII (Suppl.), 35-38, 1992.
- (9) Danilos J., Zbroja-Sontag W., Baran E., Kutylcio L., Kondratowicz L., Jusiak L. *Preliminary studies on the effect of Ukrain (Tris [2-(5BS-(5BA,6B, 12BA))-5B,6,7,12B,13,14-hexahydro-13-methyl(1,3) benzodioxolo[5,6-C]-1-3-dioxolo[4,5,i]phenanthridinium-6-OL]-ethaneaminy])phosphinasulfide-6HCl) on the immunological response in patients with malignant tumours*. Drugs Exptl. Clin. Res., XVIII (Suppl.), 55-62, 1992.
- (10) Liepins A. *Enhancement of cell mediated lysis on tumor cells by Chelidonium Majus L. alkaloids (Ukrain)*. J. Cancer Res. Clin. Oncol., 116 (Suppl.), A3 118.10, 1990.
- (11) Nowicky J.W., Staniszewski A., Zbroja-Sontag W., Slesak B., Nowicky W., Hiesmayr W. *Evaluation of thiophosphoric acid alkaloid derivatives from Chelidonium Majus L. ("Ukrain") as an immunostimulant in patients with various carcinomas*. Drugs Exptl. Clin. Res., XVIII, 139-143, 1991.
- (12) Slesak B., Nowicky J.W., Harlozinska A. *In vitro effects of thiophosphoric acid derivatives from Chelidonium Majus L. on normal lymphocyte subpopulation*. J. Cancer Res. Clin. Oncol., 116 (Suppl.), A3.112.50, 1990.
- (13) Slesak B., Nowicky J.W., Harlozinska A. *In vitro effects of Chelidonium Majus L. alkaloid thiophosphoric acid conjugates (Ukrain) on the phenotype of normal human lymphocytes*. Drugs Exptl. Clin. Res., XVIII (Suppl.), 17-21, 1992.
- (14) Hohenwarter O., Strutzenberger K., Katinger H., Liepins A., Nowicky J.W. *Selective inhibition of in vitro cell growth by the anti-tumour drug Ukrain*. Drugs Exptl. Clin. Res., XVIII (Suppl.), 1-4, 1992.
- (15) Liepins A., Nowicky W. *Ukrain is selectively cytostatic and/or cytotoxic to human tumour and HIV-infected cells but not to human normal cells*. Recent Advances in Chemotherapy. Anticancer Section. Proceedings of the 17th International Congress of Chemotherapy, Berlin, 1991.
- (16) Sotomayor E., Rad K., Lopez D.M., Liepins A. *Enhancement of macrophage tumoricidal activity by the alkaloid derivative Ukrain. In vitro and in vivo studies*. Drugs Exptl. Clin. Res., XVIII (Suppl.), 5-11, 1992.
- (17) Nowicky J.W., Nowicky W., Liepins A. *Cytostatic and cytotoxic effects of Ukrain on malignant cells*. 8th Mediterranean Congress of Chemotherapy, Athens, Greece, May 1992. J. Chemioterapia, 5 (Suppl. 1), 797, 1993.
- (18) Liepins A., Nowicky J.W. *Activation of spleen cell lytic*

activity by the alkaloid thiophosphoric acid derivative: *Ukrain*. *Int. J. Immunopharmacol.*, 14, 1437, 1992.

(19) Nowicky J.W. *New immuno-stimulating anti-cancer preparation "Ukrain"*. 13th International Congress of Chemotherapy, Vienna 1983. PS 12 5 33/A-6, part. 288/57.

(20) Nowicky J.W., Llepins A., Staniszewski A., Slezak B., Nowicky W., Hiesmayr W. *The malignotoxic and immune modulating property of the alkaloid derivative Ukrain*. *J. Cancer Res. Clin. Oncol.*, 118 (Suppl.), VI.09.05, 1992.

(21) Vatanasapt V. et al. *Preliminary report on clinical experience in the use of Ukrain*. *Thai Cancer J.*, 17, 20, 1991.

(22) Kampf M. et al. *Some problems involving in vitro cellular cytotoxicity assay*. *Natl. Cancer Invest.*, 37, 37, 1973.

(23) Miller A. et al. *Reporting results of cancer treatment*. *Cancer*, 47, 207, 1981.

(24) Pittman K. et al. *Pharmacokinetics of 5-Fluorouracil in colorectal cancer patients receiving interferon*. *Ann. Oncol.*, 4, 515, 1993.

(25) Tsujimura T. et al. *Treatment of advanced gastric and colorectal cancer with 5-FU, leucovorin and interferon-alpha*. *Gan.To. Kagaku. Ryoho*, 20, 493, 1993.

(26) Mitomi T. et al. *Randomized controlled study on adjuvant immunotherapy with PSK in curatively resected colorectal cancer*. The Cooperative Study Group of Surgical Adjuvant Immunotherapy for Cancer of Colon and Rectum. *Gan. To. Kagaku Ryoho.*, 16, 2241, 1989.

## COMPARATIVE EVALUATION OF THE COMPLEX TREATMENT OF RECTAL CANCER PATIENTS (CHEMOTHERAPY AND X-RAY THERAPY, UKRAIN MONOTHERAPY)

BONDAR G.V., BOROTA A.V., YAKOVETS Y.I., ZOLOTUKHIN S.E.

Donetsk Regional Anti-Cancer Center, Donetsk, Ukraine.

**Summary:** A total of 48 patients suffering from rectum cancer were included in this randomized study conducted at the Proctology Department of the Donetsk Regional Anti-Cancer Center. Patients in group I (24 patients) received an intensive course of high fractional X-ray therapy (cumulative dose up to 25 Gy) with direct protracted endolymphatic chemotherapy with 5-fluorouracil (5-FU) instilled in 600 mg/m<sup>2</sup> each day before operation, up to a cumulative dose of 5 g. The 24 patients in group II were treated with Ukrain as monotherapy, 10 mg each second day before operation (up to a cumulative dose of 60 mg) and a total of 40 mg after surgical intervention. Repeated Ukrain courses (100 mg/per course) were also given 6 months after surgical operation. In each case preoperative treatment was followed by routine surgical operation. Prolongation morbi were found to have developed 14 months later in six patients in group I (25.0%), whereas in group II they were found only in two cases (8.3%). Comparative investigation of objective and subjective signs, analysis of results of instrument and X-ray data, as well as dynamic study of the histological structure of rectal tumors, indicate that Ukrain exerts a more potent malignotoxic and immunomodulating action than other types of anticancer treatment.

### Introduction

The unsatisfactory results of 5-fluorouracil (5-FU) application for the treatment of colorectal cancer patients as well as its high toxicity drives the search for new, more effective remedies (1, 2). The chelidonin thiophosphoric acid derivative Ukrain (USA patent No. 4.970.212, 1990) seems to be a

promising agent for the treatment of colorectal cancer. The special immunological activities of Ukrain (NSC-631570) have been demonstrated not only *in vitro* (3-8), but also *in vivo* and in clinical studies (9-13). The malignotoxic properties of Ukrain have been tested on different cancer cell culture lines, *i.e.*, EORTC, the Netherlands: E90/029, W122, UKRS-22; NSC-62388657 National Cancer Institute, USA NSC: 63 1570-W/1 (14, 15). In addition, Nowicky *et al.* have reported increased tumoricidal action of Ukrain on murine adenocarcinomas (11).

---

Address for correspondence: A.V. Borota, Donetsk Regional Anti-Cancer Center, Polotskaya Str. 2-A, Donetsk, 340092, Ukraine



Comparative assessment carried out at the National Cancer Institute (Bethesda, Maryland, USA) revealed that the cytotoxic effect exerted by Ukrain upon human colon carcinoma cell culture lines (Cola 205, DLD-1, HCC-2998, HTC-116, HT29, KM12, KM20L2, SW620) was 100-fold higher than the cytotoxic effect of routinely used 5-FU (13). As was pointed out in the EORTC study, the colorectal cell line CXF displays high sensitivity to toxic Ukrain action. The malignotoxic properties of Ukrain *in vitro* are now undoubted, but special study of the correlation between the effects of Ukrain *in vitro* and clinical experience needs to be carried out. The purpose of this study was to investigate the above-mentioned problem and to evaluate the efficacy of Ukrain as a new potent drug in the treatment of colorectal cancer.

It is quite understandable that any cytostatic drug exerting malignotoxic action inevitably leads to general toxic action and immune system suppression in colorectal cancer patients. Oncological therapy would ideally require maximum toxicity against tumor cells and minimal toxicity to the organism. Special attention has been drawn to the stimulation of the immune system. Ukrain seems to be a good combination of the above-mentioned properties (12). In this study, based on clinical observation, we tried to estimate the therapeutic possibilities of Ukrain in the treatment of a severe disease like colorectal cancer, in comparison with traditionally used radiation therapy and endolymphatic chemotherapy with 5-FU

#### Patients and methods

A total of 48 patients (30 men and 18 women) suffering from rectal cancer or who had been treated at the Proctology Department of the Donetsk Regional Anticancer Center were enlisted in a randomized study which was approved by the Ethics

Commission of the Center. The patients' ages ranged from 36-66 years, the mean value was 56.3 years. The experimental groups were made up of patients with rectal tumors corresponding to T3-4N0M0 and T3-4N1-3M0 stages of TNM classification without severe accompanying disease or complications of the basic process. Histological verification of tumors carried out in each case before starting the special treatment revealed adenocarcinomas at different degrees of differentiation in 89.7% of cases

All patients were subdivided into two randomized groups. Patients in group I (n=24) received a preoperative intensive course of high-fractional X-ray therapy (6 Gy daily, up to 25 Gy) with direct endolymphatic chemotherapy with 5-FU (600 mg/m<sup>2</sup> daily), up to a cumulative dose of 5 g. After preoperative treatment all patients underwent a surgical operation. Group II comprised 24 patients who received monotherapy with Ukrain (Nowicky Pharma, Vienna, Austria): i.v. injections of 10 mg each second day before surgical operation (up to 60 mg cumulative dose) and a total of 40 mg during the postoperative period. Additional repeated courses (100 mg Ukrain per course) were performed 6 months after surgical intervention.

Only patients without verified distant metastases were included in the randomized study. Metastatic invasion into regional lymphatic glands was found in 56.3% of cases (Table I). Where necessary, patients received corrective infusion, cardiotropic and general reinforcement therapy.

The complex preoperative study involved the determination of tumor dimensions and mobility, general and biochemical analysis of the blood and urine, assessment of immune status (T- and B-lymphocytes count, concentrations of immunoglobulins A, M, G; plasma content of the circulating immune complexes (CIC) and phagocytic activity of neutrophils). In addition, the immune-enzymatic method was used to determine the blood content of

**Table I** Distribution of colorectal cancer patients according to TNM-classification

TNM staging	Patient groups	
	5-FU + X-ray therapy	Ukrain therapy
T3N0M0	2	1
T3N1M0	2	2
T3N2M0	1	1
T3N3M0	3	1
T4N0M0	8	10
T4N1M0	1	2
T4N2M0	3	2
T4N3M0	4	5
Total	24	24

5-FU = 5-fluorouracil

$\alpha$ -fetal protein (AFP) and carcino-embryonal antigen (CEA). Additional topographical data were obtained by means of abdominal sonography and computerized tomography. X-ray studies of the lungs and other examinations were also performed. Tumor dimensions, as measured by rectoscopy, fibroscopy and irrigoscopy, varied from  $2.8 \pm 3.4$  cm to  $8.6 \pm 9.8$  cm.

## Results

After finishing the specific preoperative treatment for each group, repeated dynamic followup examinations were performed. These included assessment of patients' general condition, expression of pain syndrome, and measurement of tumor dimensions. The toxicity of chemotherapy with reference to its influence on hemopoiesis was also determined for all groups of patients. The most expressed signs of the toxic action of chemotherapy were found in patients in group I who received combined endolymphatic chemotherapy and radiation therapy. The mean value of the Karnofsky Index decreased from 71.3 to 66.4. In contrast, practically no toxic effects were found in patients in group II, treated with Ukrain. Moreover, in these patients an improvement in the general condition and appetite was observed, as well as the disap-

pearance of partial intestine impassability. Group II patients displayed a certain improvement in hemopoiesis with a statistically significant rise in erythrocyte and lymphocyte counts, while patients treated with combined endolymphatic chemotherapy and radiation therapy showed a tendency to develop anemia and lymphopenia. The Karnofsky Index increased to 78.3% from 70.8%. The most pronounced changes in immune status were also observed in group II patients who received Ukrain monotherapy (Table II). In this group a substantial rise in the T- and B-lymphocyte counts, increased phagocytic activity of neutrophils, and an increased content of immunoglobulins A, M, and G were observed. Reduced plasma concentration of AFP, CIC and CEA was characteristic for group II patients. No marked changes in immune status were detected in group I patients.

Reduced tumor dimensions were found in both groups of patients after preoperative therapy. Preoperative X-ray therapy in combination with endolymphatic 5-FU led to resorption of tumors in up to 18% of cases, while the mean value of tumor resorption with Ukrain monotherapy was 22%. Various kinds of rectal resection were performed following preoperative therapy. The majority of the surgical interventions (95.2%) were sphincter-saving in character and involved various kinds of abdominal-anal resections of the rectum. Two

Table II Some parameters characterizing the immune status and hemopoiesis of patients

Parameters	5-FU + X-ray therapy		Ukrain therapy	
	before	after	before	after
Erythrocytes	3.9 ± 0.35	3.4 ± 0.21	3.9 ± 0.36	4.11 ± 0.24
Leukocytes	9.2 ± 0.96	7.4 ± 0.88	9.3 ± 1.21	9.1 ± 1.51
Lymphocytes	23.8 ± 3.17	17.6 ± 2.17	23.9 ± 4.01	28.6 ± 4.12
Rod-shaped	11.8 ± 2.57	13.8 ± 3.21	12.1 ± 2.56	9.4 ± 8.87
Segmented	55.8 ± 3.7	57.6 ± 2.96	55.3 ± 3.61	53.4 ± 3.58
Eosinophils	3.5 ± 1.11	2.8 ± 0.93	3.2 ± 0.64	4.3 ± 1.24
Monocytes	5.6 ± 1.09	5.9 ± 1.13	6.1 ± 1.13	5.8 ± 1.08
Proteins	71.02 ± 2.18	67.4 ± 1.31	69.2 ± 2.03	76.1 ± 2.67
Bilirubin	18.1 ± 3.12	21.6 ± 3.18	18.6 ± 2.64	16.9 ± 2.21
T-lymphocytes	36.8 ± 2.86	34.1 ± 2.79	39.3 ± 3.26	46.2 ± 3.48
B-lymphocytes	9.12 ± 1.37	8.4 ± 1.82	9.14 ± 1.36	11.2 ± 2.71
Neutr. phag. activ	80.2 ± 1.91	65.4 ± 1.51	66.4 ± 2.02	98.1 ± 2.1
CIC	279.2 ± 17.6	296.1 ± 19.31	273.1 ± 18.1	211.6 ± 15.31
AFP	28.7 ± 2.81	30.1 ± 3.03	26.2 ± 2.01	5.1 ± 0.64
CEA	4.8 ± 1.02	4.5 ± 0.87	4.8 ± 0.91	1.2 ± 0.18
MCA	16.2 ± 1.83	18.4 ± 2.12	17.8 ± 1.93	4.1 ± 0.76
IgA	2.93 ± 0.86	3.14 ± 0.56	2.87 ± 1.17	4.12 ± 1.63
IgM	0.76 ± 0.11	0.86 ± 0.18	0.72 ± 0.12	0.96 ± 0.21
IgG	12.6 ± 1.85	14.2 ± 1.47	12.8 ± 1.42	19.1 ± 2.34

5-FU = 5-fluorouracil, CIC = circulating immune complexes, AFP =  $\alpha$ -fetal protein, CEA = carcino-embryonal antigen, MCA = mucin-cancer antigen.

patients with tumors of the anal canal underwent resection according to Keny-Myise. In total, postoperative complications developed in nine (18.8%) cases. Postoperative complications were found to develop mainly in patients from group I – 7 cases (29.1%). In contrast, no postoperative purulent inflammatory complications were revealed in group II patients. Atony of the urinary bladder developed in two (8.3%) patients treated with Ukrain monotherapy.

Clinical observation of all patient groups was conducted for a period of 14 months. Six months after the first course of Ukrain monotherapy, all patients in group II were subjected to repeated Ukrain treatment with 10 mg i.v. every other day, up to a cumulative dose of 100 mg. In the course of observation of group I patients who received complex chemotherapy and X-ray therapy, the continuation of tumor development was observed in eight

cases (33.3%). Relapses of the colorectal tumor into the small pelvis parenchyma were registered in five cases (20.8%) and metastases to the liver in three cases (12.4%). These problematic patients were subjected to a repeated course of the complex chemotherapy and X-ray therapy. One patient (4.1%) with metastatic liver injury died 11 months following surgical intervention.

In contrast, prolongation morbi were detected in only four patients (16.6%) in group II who received Ukrain monotherapy during pre- and postoperative periods. Of these, one man had a tumor relapse in the pararectal parenchyma, and one woman had multiple metastases to the liver. The man was subjected to an additional two courses of therapy with Ukrain (100 mg per course) in combination with X-ray treatment aimed at the site of the relapse. This succeeded in stabilizing the situation. The woman received symptomatic hepatotropic therapy. In all

cases prolongation morbi were revealed in patients who had metastasis in regional lymphatic nodes.

## Discussion

Ukrain monotherapy considerably improved the state of oncological patients before surgical intervention, while radiation and chemotherapy caused immune system suppression and impairment of some metabolic and homeostatic mechanisms. These led to a worse prognosis for further treatment. It must be mentioned that pronounced sclerosis and heavy bleeding of the minor pelvic tissues during surgical intervention, which normally occurs after chemo- and radiation therapy, proved to be practically absent after Ukrain pretreatment. The latter proved to facilitate considerably surgical interventions and to bring about fewer intra- and postoperative complications. Over 2 years observation, eight group I patients (33.3%) had rectal cancer relapses and four group II patients (16.6%) experienced rectal cancer relapses. This is certainly indicative of the greater efficiency of the complex therapy based on Ukrain administration in colorectal cancer patients.

## Conclusion

The data obtained in the course of this randomized investigation of patients suffering from tumors located in the ampullar part of the rectum points to the conclusion that Ukrain monotherapy exerts a more powerful anticancer and immune system stimulating effect in comparison with traditional, broadly-used 5-FU chemotherapy in combination with X-ray treatment. Therefore, we can recommend Ukrain as the most effective preparation for adjuvant therapy of colorectal cancer.

## References

- (1) Nichols P.H., et al. *Peri-operative modulation of cellular immunization in patients with colorectal cancer*. *Exp. Immunol.*, 94, 4, 1993
- (2) Punt C. J., et al. *Continuous infusion of high-dose 5-fluorouracil in combination with leucovorin and recombinant interferon- $\alpha$ -2b in patients with advanced colorectal cancer. A multicenter Phase 2 study*. *Cancer*, 72, 2107, 1993
- (3) Chłopkiewicz B., Marczevska J., Ejchart A., Anusewska E., Koziorowska J. *Evaluation of mutagenic, genotoxic and transforming properties of Ukrain*. *Drugs Exptl Clin Res.*, XVIII (Suppl.), 31, 1992
- (4) Juszkiewicz T., Minta M., Włodarczyk B., Biernacki B. *Teratological evaluation of Ukrain in Hamsters and rats*. *Drugs Exptl. Clin. Res.*, XVIII, 23, 1992
- (5) Kleinrok Z., Jagiello-Wojtowicz E., Matuszek B., Chodkowska A. *Basic central pharmacological properties of thiophosphoric acid alkaloid derivatives from Chelidonium majus L*. *Pol J. Pharmacol Pharm.*, 44, 227, 1992
- (6) Kleinrok Z., Jagiello-Wojtowicz E., Nowicky J.W., Chodkowska A., Feldo M., Matuszek B. *Some pharmacological properties of prolonged administration of Ukrain in rodents*. *Drugs Exptl Clin Res.*, XVIII (Suppl.) 93, 1992.
- (7) Remiszewska M., Wutkiewicz M., Jastrzebski Z., Czyzewska-Szelan H., Danysz A. *Pharmacological effects of Ukrain in rats and rabbits*. *Acta Pol Pharm.*, 49, 43, 1992
- (8) Wyczolkowska J., Czujaj M., Maslinski C. *The immunomodulating preparation Ukrain does not induce anaphylactic sensitization in mice and guinea pigs*. *Drugs Exptl Clin Res.*, XVIII (Suppl.), 35, 1992.
- (9) Danilos J., Zbroja-Sontag W., Baran E., Kutylicio L., Kondratowicz L., Jusiak L. *Preliminary studies on the effect of Ukrain (Tris[2-(5SA-(5BA,6B,12BA)) 5B,6,7,12B,13,14-hexahydro-13-methyl [1,3] benzodioxolo [5,6 C] 1S-dioxolo [4,5,1] phenanthridinium-6-yl]-ethaneaminy]) phosphinesulfide 6HCL) on the immunological response in patients with malignant tumors*. *Drugs Exptl Clin Res.*, XVIII (Suppl.), 55, 1992
- (10) Liepins A. *Enhancement of cell mediated lysis on tumor cells by Chelidonium Majus L alkaloids; (Ukrain)*. *J. Cancer Res. Clin. Oncol.*, 116 (Suppl.), 10, 1990
- (11) Nowicky J.W., Saniszowski A., Zbroja-Sontag W., Slesak B., Nowicky W., Hiesmayr W. *Evaluation of thiophosphoric acid alkaloid derivatives from Chelidonium majus L ("Ukrain") as an immunostimulant in patients with various carcinomas*. *Drugs*

Bondar G.V. et al

Exptl Clin Res, XVIII, 139, 1991

(12) Slesak B., Nowicky J.W., Harlozinska A. *In vitro* effects of thiophosphoric acid derivatives from *Cheilanthes Majus L.* on normal lymphocyte subpopulation. J. Cancer Res. Clin. Oncol. 116 (Suppl.) 50, 1990

(13) Slesak B., Nowicky J.W., Harlozinska A. *In vitro* effects of *Cheilanthes majus L.* alkaloid thiophosphoric acid conjugates (Ukrain) on the phenotype of normal human lymphocytes. Drugs Exptl Clin Res. XVIII (Suppl.), 17, 1992

(14) Hohenwarter O., Strutzenberger K., Katinger H., Liepins A., Nowicky J.W. Selective inhibition of *in vitro* cell growth by the anti-tumour drug Ukrain. Drugs Exptl Clin. Res., XVIII (Suppl.), 1, 1992

(15) Liepins A., Nowicky J.W. Ukrain is selectively cytostatic and/or cytotoxic to human tumour and HIV- infected cells but not to human normal cells. Recent Advances in Chemotherapy Anticancer Section Proc. 17th Int. Cong. Chemother. (Berlin, 1991), 1620

An  
**Alternative  
Medicine**

Definitive Guide to

**CANCER**

W. JOHN DIAMOND, M.D.

AND W. LEE COWDEN, M.D.

WITH BURTON GOLDBERG



FUTURE MEDICINE PUBLISHING, INC.  
Tiburon, California

STRATEGY	DOSAGE/KEY COMPONENTS	FOR MORE INFORMATION see page #
Vitamin C	as determined by physician	786
Vitamin E	as determined by physician	790
Selenium	as determined by physician	785
L-cysteine, N-acetylcysteine, and glutathione	as determined by physician	377/693 868
L-arginine	as determined by physician	762
Coenzyme Q10	as determined by physician	766
Bioflavonoids	variable, depending on supplement	817

**Psychosocial Support for Cancer Patients**

Counseling and ongoing communications  
encourage a "fighting spirit" attitude, a more assertive, active participatory role in healing same as above

Support groups

**CAUTIONS**

This chapter includes information regarding actual treatments used by Dr. Atkins only after his careful diagnosis of each patient. All cancer patients are unique. Do not administer these treatments to yourself or others. Discuss these treatments with your physician or other qualified health-care professional. Readers should not interpret this material as therapeutic advice, but should see a physician in all cases.

getting worse, as indicated by various blood tests (cancer markers), but then improved dramatically when he administered the botanicals and nontoxic medicines central to his program. "In my view, cancer is a controllable chronic illness, rather than an illness that will destroy you unless you totally eradicate it, as conventional medicine considers it," says Dr. Atkins. "Alternative and complementary doctors are not only concerned with attacking the cancer; we're also supporting the body fully, striving to make it stronger so that it can fight cancer for us, rather than just sit on the sidelines, not being allowed to perform its usual cancer-controlling functions."

For the past 10 years Dr. Atkins has investigated a large number of alternative cancer therapies. Today he concludes that these alternative methods are every bit as powerful as their conventional counterparts, and work without the harmful side effects of radiation or chemotherapy. Through his multifaceted program, Dr. Atkins seeks the ideal environment for the

body to overcome cancer, emphasizing substances that selectively kill the tumor while encouraging the growth of normal cells and tissues. Chemotherapy has never been able to do this, Dr. Atkins notes.

"Cancer control is a tug of war between you and the disease," Dr. Atkins says. "As the cancer gains strength, it pulls you over the center line and into the pit. The key to winning is to add your own 'power pullers' in this tug of war, that is, natural substances that help your body destroy only the cancer, while strengthening the immune system." Dr. Atkins' "power pullers" include Ukrain, 714X, shark cartilage, Carnivora, mistletoe, and other substances that can help reverse even the most advanced forms of cancer.

Many of these medicinal substances are delivered intravenously or by injection to expose the person to concentrated dosages and to prevent their inactivation that would be caused by digestion. The program also involves the daily oral administration of nutritional and herbal therapies. "The exciting concept that mainstream oncologists do not grasp is that these are nontoxic and that the benefit-to-risk ratio is nearly infinity-to-zero," says Dr. Atkins.

**SUCCESS STORY  
Reversing Ovarian Cancer**

At 52, Claudette began having bouts of fatigue, weakness, and depression, and was losing a considerable amount of weight. After visiting her gynecologist for a routine checkup, Claudette was told she had an ovarian cyst and would need an operation. After undergoing surgery to remove both ovaries, she was diagnosed as having ovarian cancer that had spread to the tissues supporting the stomach and adjacent organs.

Claudette's doctors wanted her to begin immediately a 6-month chemotherapy course, telling her that after a year they would do exploratory surgery. But Claudette had decided otherwise and consulted with Dr. Atkins. "I knew that chemotherapy was not for me," says Claudette. "I felt that if I were ever to die from cancer, then let it be from the disease and not the 'cure.' Perhaps I would become a statistic for something I believe in."

instead, they were furious. Phone calls ensued from her oncologist, surgeon, and gynecologist, all telling her she was crazy. "When I met with Dr. Atkins for the first time, I told him that my orthodox doctors told me I couldn't be cured. Dr. Atkins replied, 'You should finish that sentence differently: You can't be cured ... by them.'"

Claudette was immediately started on Dr. Atkins' anticancer program. Within 2 weeks of her initial intravenous treatments, Claudette began feeling stronger. "It was a marvelous feeling. I was blossoming like a flower. After a short time, I regained my appetite, went on shopping sprees with my daughter, even went to shows. I began to live again! Can I ever repay Dr. Atkins for giving me the gift of life? Perhaps not. But if I stay well and healthy, I think that will be his greatest reward."

For the next 2½ years, Claudette came in for regular follow-ups. Her program consisted of a sequence of intravenous treatments using many of the substances discussed below. Claudette has shown no signs of a relapse since. Her treatments are monitored every 4-6 weeks and her results consistently improve. Today, more than 3 years after beginning treatment, Claudette continues to live a normal and fruitful life.



An **intestinal polyp** is a mass of tissue, roughly spherical in shape, at the end of a stalk. The polyp bulges outward from the normal intestinal surface. It may be either benign or malignant, having arisen from the focus of an inflammation or a degenerative lesion.

## SUCCESS STORY

### Reversing Colon Cancer

After David, 52, underwent a visual examination of the inner surface of his colon by colonoscopy, which discovered four large polyps, his doctors called him a "grower." For almost a year he had been in and out of hospital for tests, probings, examinations, operations, and countless blood transfusions. At one point, his doctors, short on theories, said that his problem was probably caused by hemorrhoids. During yet another operation, David's surgeons not only found a tumor behind his intestine, but saw that he had an extra 3 feet of intestines. Although they assured him that they saved his life, shortly after his symptoms started returning.

When his doctors told him chemotherapy was the only viable treatment, David asked if there were any alternative treatments. "No such thing," they replied. But because David was a medical equipment supplier, he had seen what chemotherapy patients go through and wanted none of it. "I knew that was not the way I wanted to live my life. That's also when I

knew I had to see Dr. Atkins. I was convinced that Dr. Atkins would be able to treat me because, the way I see it, if his treatment is a natural one with vitamins and minerals, and my body is made up of chemicals, then what harm could he cause me?"



CT (computed tomography) scan, formerly CAT scan, is X-ray technique that provides a detailed cross-section view of tissue structure in the part of the body being scanned; useful for detecting tumors, fluid accumulations, and certain bone and spine abnormalities.

David began Dr. Atkins' nutritional program with oral supplements, immune boosters, and intravenous infusions. The next month, he received the anticancer formula by intravenous infusion once a week along with daily dosages of 714X. "After the first treatment, I was happy there were no side effects," said David. "No fatigue or nausea. By the third and fourth treatment, I started to experience a warmth throughout my body. I was walking more with no more fatigue. I could actually feel my body building itself up. I felt reborn!" David regained his formerly hearty appetite and put on 14 pounds. After 7 months, his IV treatments were reduced to once every 2 weeks.

A year after starting treatment, the frequency of David's IVs was reduced to once every 3 weeks, and he continued receiving 714X. His tumor markers remained within the normal range, indicating no growth of cancer. Ten months later, he began a Ukrain protocol; then, 2 months after that, Dr. Atkins conducted a CT scan of his abdomen and pelvis. It came out completely normal.

When David went in for a colonoscopy the next month, the test found nothing significant and he was negative for intestinal polyps. Today, more than 3 years after beginning treatment, David continues his regular visits to the Atkins Center every 2-3 weeks. He lives a normal life and still holds down 2 jobs. "I know there is no more cancer in me," says David. "My energy level is beyond anyone's imagination. I'm looking forward to 60 more years of life, and then some."

### The Importance of Choosing the Right Therapy

"The key to success in alternative medicine approaches to cancer is to gather as much data as possible on each patient, then to apply what I call the 'Hippocratic pecking order,'" says Dr. Atkins. This means using the more benign, nontoxic therapies first and saving the riskier, more invasive therapies for last, if ever. Data collection involves studying the patient's immune system and the status of its key T and B cells in detail. Dr. Atkins



ble febrile reaction, as this seems to provide optimal response.

Dr. Atkins regards Ukrain as the single best anticancer agent he has used to date. "Like chemotherapy, it kills cancer cells very well but, unlike chemotherapy, it spares normal, healthy tissue. If the medical community were willing to give it a try, Ukrain could replace chemotherapy in treating almost all cancers." The majority of terminal cancer patients would benefit from Ukrain through the reduction or stabilization of their cancers as well as through the consistent improvement in their immune cell counts that Ukrain produces, says Dr. Atkins. Of the first 52 people who came to the Atkins Center and were treated with Ukrain, 40 have achieved a significant degree of benefit.

One of Dr. Atkins' patients, a woman with pancreatic cancer, at first showed definite improvement in her condition, then "suffered a relapse when the supply of Ukrain was cut off by officials from the FDA," Atkins says. "Within days of resuming her Ukrain injections, she had dramatic relief from her cancer pain and other symptoms." When a young woman with non-Hodgkin's lymphoma started using Ukrain and various other nontoxic, immune-enhancing therapies, the tumors in her abdomen shrank consistently after each treatment—without the help of chemotherapy.

At the same time, her energy levels and immune-system profile (numbers and activities of key immune cells) improved weekly for the next two years. This case and many others recorded by Dr. Atkins clearly shows that using Ukrain early in cancer treatment, or soon after the diagnosis, produces the best results.

Despite its potential to target cancer cells, bolster immunity, and prolong life, Ukrain's published cure rate (a statistical measure, based on group studies) is still low. This is in part because inappropriately low dosages have been used in the controlled studies, says Dr. Atkins. Because Ukrain's production costs are very high—\$20 per cc administered—and European hospitals conducting the tests have limited funds, many studies limited treatment to 10 of the 10-cc injections. "In actual practice, 50 to 100 of these injections are needed," Dr. Atkins says. "Perhaps once the research is done

**In most cases, Dr. Atkins suggests "holding off" on chemotherapy and conventional treatments unless it becomes clear that the safer treatments alone are not getting the job done.**

### **The Atkins Injectable Program**

**Ukrain**—This substance is derived from a combination of a common weed called celendine (*Chelidonium majus*) and thiophosphoric acid (also called thiolepa, one of the original chemotherapeutic agents). This combination appears to neutralize the toxic effect of the alkaloids contained in the plant. By this method, Ukrain has been rendered almost completely nontoxic.

Ukrain does not harm the body's healthy tissues and anticancer defenses; to the contrary, it actually fortifies them.<sup>7</sup>

"Ukrain is clearly a potent anticancer agent and also a very safe and supportive one," says Dr. Atkins. "So it fits into our cancer treatment system very well. Ukrain may soon become recognized as alternative medicine's most effective nontoxic tumor destroyer." According to recent clinical studies, the optimal dosages for Ukrain appear to be 15 to 20 days of 5-20 mg Ukrain per injection, usually given 3 times a week, depending on the individual patient's condition.<sup>1</sup> Dr. Atkins advises doctors who work with advanced cancer patients to find the dose that causes a mild, tolera-

**When a young woman with non-Hodgkin's lymphoma started using Ukrain and various other nontoxic, immune-enhancing therapies, the tumors in her abdomen shrank consistently after each treatment—without the help of chemotherapy.**

"... stop dragging its feet and designate the funding necessary to investigate Ukrain."<sup>4</sup>

**714X**—Developed by Canadian biologist Gaston Naessens, 714X is composed of ammoniated camphor and other substances. 714X is thought to neutralize a substance produced by tumor cells, one that ordinarily paralyzes the immune system; 714X acts to prevent this substance from protecting cancer cells. "The 714X compound doesn't kill the cancer cells directly but blocks them from feeding themselves," says Dr. Atkins, adding, "Even though it was studied as a single therapy, I find it to be a valuable adjunct to other treatments."

**"714X doesn't kill the cancer cells directly but blocks them from feeding themselves," says Dr. Atkins. "I find it to be a valuable adjunct to other treatments."**

Dr. Atkins cautions that patients undergoing the 714X treatment should not take therapeutic doses of vitamin E or vitamin B12 at the same time, as the 2 vitamin supplements may interfere with its therapeutic action. The only side effects from 714X his patients have reported are transient burning sensations at or around the site of injection.

The treatment consists of at least 3 consecutive series of 714X injected directly into the lymphatic nodes of the groin, once a day for at least 21 consecutive days.

This is followed by a break of 2 days to allow the patient to rest while the natural defenses of the body are restored. People with advanced cases of cancer can receive more intense and prolonged therapy, since 714X has no harmful side effects.

**Mistletoe**—Fermented extracts of mistletoe, or *Viscum album*, (known by their brand names, Iscador and Helixor) have been used by European physicians since 1920.

European anthroposophical doctors, practicing a type of medicine founded by Rudolf Steiner, who discovered mistletoe as an anticancer remedy, claim the best results overall have been with the treatment of solid tumors before and after surgery and radiation treatment. "We really don't know why mistletoe works, but the German doctors have used it successfully for decades," Dr. Atkins says. "They're the real experts, which is why I tend to follow their programs." Dr. Atkins administers Iscador every oth-

er month, when Ukrain is not being given, and usually along with 714X. The typical course of mistletoe treatments consists of 10 to 16 injections given in increasing concentrations.

**Carnivora**®—This substance, derived from Venus flytrap, has been studied primarily by Helmut Keller, M.D., in German cancer treatment clinics, where excellent results have been obtained. "The reason these results are impressive is that they show that the treatment 'works' and is suitable to act as an effective partner to other nontoxic treatments that also work," says Dr. Atkins. "Carnivora may work in a different way from other therapies, by rendering the tumor less malignant rather than by destroying any tissue." After the intravenous program is completed, intramuscular injections of Carnivora may be carried out several times a week until the treatment program is finished. Even more of Atkins' patients take an herbal decoction of Venus flytrap every day.

**Amygdalin/Laetrile**—This substance is highly concentrated in the pits of apricots, peaches, cherries, and berries. As one of a group of substances called nitrilosides, amygdalin has been found to have strong cancer-fighting potential, particularly with regard to secondary cancers, including a 60% reduction in lung metastases.<sup>5</sup> Some research indicates that it can extend the lives of both breast and bone cancer patients.<sup>6</sup> "Amygdalin appears to neutralize the oxidative cancer-promoting compounds such as free radicals," says Dr. Atkins. "It's just one more key component for keeping cancer from growing or spreading. Contrary to what people have said about laetrile, amygdalin's former name, it should be considered an effective, entirely safe treatment for all types of cancer." Amygdalin may be used every month, as an alternative to Ukrain.

**Oxygenating Therapies**—Atkins favors the use of compounds, such as germanium sesquioxide, which enhance the availability of oxygen to both healthy cells and cancer cells. The reason is that cancer cells cannot thrive under oxygen-rich conditions. "These compounds take advantage of cancer's basic inability to use oxygen as a fuel source," says Dr. Atkins. "They reinforce the effects of other therapies for this reason." Germanium sesquioxide blocks or slows the growth of tumors and significantly lengthens sur-

## Cancer Medicine Kill Jackie Kennedy before Her Time?

Jackie Kennedy's fight with cancer is one of Dr. Atkins' favorite examples of how conventional medicine treats cancer. From the very beginning, orthodox oncologists take a illness which has a 50-50 chance of reversal and by their actions they seem to say we're then going to cure her or kill her. Early in the course of her treatment, they began pouring chemotherapy into her brain. When this intensely toxic treatment failed, the illness was able to run away like a brushfire. It led to the rapid demise of Jackie Kennedy, which is virtually unheard of in an untreatable case of lymphoma.

Dr. Atkins points out that the same kind of mis-treatment nearly occurred with the late baseball player Mickey Mantle, who died from lung cancer and complications related to conventional treatment. As weak as Mantle was in the final weeks, some of his doctors wanted to give him even more chemotherapy. Dr. Atkins says: "They were absolutely determined to use every toxic weapon in their arsenal, with our really understanding how his body's natural defenses would be compromised." In Dr. Atkins' view, modern oncology still has a long way to go before it learns to adhere to the Hippocratic dictum of: first, do no harm.

without any side effects, so it renders chemotherapy largely unnecessary." Radiation treatments are typically futile, too, says Dr. Atkins. "In some cases, however, we need to shrink tumors if they're encroaching or im-

ping on more vital parts of the body. In that case, a combination of radiation and hyperthermia [heat treatment delivered by ultrasound or microwave] can be effective." Dr. Atkins was among the first doctors in the U.S. to successfully combine radiation with hyperthermia (heat treatment) to help treat prostate cancer.

Another option for localized tumor destruction that Dr. Atkins prefers to radiation is called Accelerated Charge Neutralization (ACN). The principle of ACN is to locate the skin area of greatest electrical differential (the difference between negative and positive charges) caused by the tumor, then to administer electrical current of the opposite charge. "This modality is perfectly safe, can destroy tumors, and works synergistically with heat therapy (hyperthermia)," says Dr. Atkins.

**In most cases of cancer, Dr. Atkins says that a complementary approach is needed, one which emphasizes alternative therapies along with limited and judicious use of conventional methods.**



For more information about heat therapy (hyperthermia), see Chapter 33: Physical Support Therapies, pp. 996-1000.

in this B vitamin.<sup>16,17</sup>

"Many people in the U.S. may be deficient in various B vitamins, notably vitamin B6, because of overconsumption of refined carbohydrate foods," says Dr. Brodie. "This may not only increase their risk of cancer, but diminish their chances of recovery." In addition to the B-complex supplement in standard doses, Dr. Brodie recommends taking extra vitamin B6 (400 mg) each day.

**Shark and Bovine Cartilage**—The main scientific rationale for using cartilage to treat cancer is that compounds in cartilage appear to "turn off" the growth of new blood vessels feeding tumors. Ordinarily, as tumors grow, their surrounding blood vessels continue to expand and multiply to meet the nutritional needs of the tumors—a process known as angiogenesis.

"In no way should cartilage be considered a cure for cancer, or by itself to be sufficient to control cancer," says Dr. Brodie. "However, when combined with other immune-enhancing agents, it has been a welcome addition to our arsenal." Although Dr. Brodie uses the cartilage from both sharks and cows (bovine), he says the bovine form is "equally effective while considerably less expensive, requiring much smaller dosages than the shark material."

**Phytochemicals**—These natural chemicals found only in plants (hence the term, "phyto") have many cancer-repelling properties.<sup>18</sup> Examples include allyl sulfides (found in garlic, leeks, and onions), dithiolthiones (in broccoli and cabbages), and indoles (most members of the cabbage family). Allyl sulfides increase the production of an enzyme that helps the body excrete carcinogens and inhibit the tumor cells' ability to reproduce. Dithiolthiones help produce enzymes that block carcinogens from damaging a cell's DNA. Indoles stimulate the activity of enzymes that can detoxify carcinogens and may make estrogen less potent, thus lowering the risk of breast cancer. Other phytochemicals include saponins, flavonoids, coumarins, protease inhibitors, thiocyanates, and isothiocyanates.<sup>19</sup>

In addition to green concentrates or "green drinks" based on concentrated plant-derived preparations that are high in phytochemicals, Dr. Brodie recommends the use of soy products, such as tofu and soy powder,

which are among the richest sources of phytochemicals. One cup of soy powder per day, mixed into beverages (soups, juices, etc.) or vegetable dishes, provides an ample amount of phytochemicals, according to Dr. Brodie.

### Innovative Patented Anticancer Substances

Dr. Brodie is studying other substances, such as Ukrain, Carnivora, and melatonin, for possible inclusion in his anticancer program. These have been developed outside the United States, chiefly owing to the restrictive attitude of the FDA toward natural and nontoxic methods for treating disease.

**Ukrain**—This compound, derived from a plant called chelidonium, has shown powerful immune-stimulating effects in people with a variety of cancers.<sup>20</sup> The main advantage of Ukrain, Dr. Brodie says, is that apparently it *selectively* kills cancer cells, and not only does it do no harm to the body's defenses, it actually fortifies them.<sup>21</sup> Based on studies of 70 cancer patients, the most appropriate dosages for Ukrain appear to be 20 days of 5, 10, 15, or 20 mg of Ukrain per injection, each day or every other day, depending on the condition of the cancer patient.<sup>22</sup>

**Carnivora**<sup>®</sup>—This unique substance is derived from Venus flytrap, a carnivorous plant. "Like Ukrain, Carnivora seems to attack tumor cells while at the same time strongly enhancing the immune system," says Dr. Brodie. The Carnivora solution is typically placed in 500-cc bottles (5 mg) and given intravenously 3-4 times a week for 1-3 months. Even higher doses have afforded better results in some cases, Dr. Brodie notes, adding that after the intravenous program is completed, intramuscular injections may be carried out 2-3 times a week for several more months.

**Melatonin and Interleukin-2 (IL-2)**—Melatonin is a powerful immune-enhancing hormone produced naturally by the brain as well as by many plants, which are the source of most melatonin supplements on the market today. When combined with IL-2, another immune-stimulating compound, melatonin

**The main advantage of Ukrain, Dr. Brodie says, is that apparently it selectively kills cancer cells, and not only does it do no harm to the body's defenses, it actually fortifies them.**

of other herbs. By working in this way, he can optimize the effectiveness of the botanical agent, particularly when a patient does not have the digestive strength to utilize the herbal medicine. The other botanicals most often recommended by Dr. Stoff for helping cancer patients recover from their illness are as follows.

**Ukrain**—Dr. Stoff frequently recommends the use of Ukrain, a derivative of celandine, for the treatment of cancer patients. “I use Ukrain for solid tumors such as breast, lung, and colon, as opposed to leukemia and myeloma,” he says. “I have found that it can be beneficial even when used in combination with Taxol. Ukrain also supports liver function in important ways.”

**Gingko Biloba**—A member of an ancient family of trees (Gingkoales) no longer found in the wild, for thousands of years, *Gingko* has been a staple of Chinese herbal medicine, recommended for coughs, asthma, and acute allergic inflammations. Recent Western research indicates this herb has useful anticancer properties, including antioxidant activity. Dr. Stoff uses *Gingko* as a blood cleanser and to enhance circulation; his typical dose is 40 mg 3 times daily.

**Panax Ginseng**—For over 2000 years, Chinese doctors have prescribed ginseng, either in the form of powder or extracts, as a general tonic to promote strength, vitality, appetite, emotional stability, and “wisdom.”<sup>16</sup> Certain components of ginseng appear to have a distinct immune-stimulating and antioxidant effect. “Ginseng is a potent adaptogenic herb which helps to support the life force,” says Dr. Stoff. “On the biochemical level, ginseng exerts a broad-based therapeutic influence, which probably accounts for its consistently supportive role in cancer therapy.” He adds that ginseng should never be taken in large doses as it may inhibit immunity.

**Echinacea and Pau D’Arco**—These 2 herbs have well-known immune-enhancing abilities. According to Dr. Stoff, the primary reason for combining *Echinacea* and pau d’arco is to provide protection against infection. “These herbs should not be considered a primary treatment for cancer,” Dr. Stoff says, “but can help immensely in the treatment of associated microbial infections, which are a common problem with advanced cancer.”

**Aloe Vera**—“I use quite a lot of aloe vera when someone has trouble with constipation or, specifically, for a failure in the production of secretory IgA (an immunoglobulin, part of the immune system response),” says Dr. Stoff. “This is not common with cancer, but very common with AIDS or chronic fatigue syndrome.” Dr. Stoff typically recommends 1 ounce of aloe concentrate in juice or water 3 times a day.

**Maitake Mushroom**—Dr. Stoff prefers to use the maitake D-fraction at 10 drops 3 times a day, mixed in water or with Ara-6 and the amino acid glutamine. “I’m finding that advanced cancer patients who show signs of wasting (serious weight loss) will greatly benefit from this combination. All 3 should be used concurrently to help the individual regain weight and to stabilize the immune system, which can become extremely compromised in the advanced cancer patient.”

**Essiac**—“This is an excellent blood cleanser and can help tremendously if someone is toxic from either chemotherapy or radiation,” says Dr. Stoff. “Patients seem to feel better taking Essiac; at some level it appears to enhance mood.”

**“Essiac is an excellent blood cleanser and can help tremendously if someone is toxic from either chemotherapy or radiation,” says Dr. Stoff. “Patients seem to feel better taking Essiac; at some level it appears to enhance mood.”**

## A Comprehensive Supplementation Program

**Melatonin**—“The brain hormone melatonin plays a major role in my practice, since it has a definite antioxidant activity, helps reset circadian cycles, and stimulates natural killer cells,” says Dr. Stoff. “Melatonin is a potent addition to treatment for a variety of cancers. I have not seen any adverse effect from using this supplement.”

Dr. Stoff’s endorsement is predicated on the melatonin being the time-release type which is available on prescription. This long-acting melatonin works better than the short-acting form available in health food stores. Dr. Stoff favors melatonin in a microcellulose base without any magnesium and vitamin B6. The optimal melatonin range Dr. Stoff recommends working with is between 1 and 10 mg.

When it comes to cancer treatment, says Dr. Stoff, patients need not

## Remissions with Ukrain

Scientists at the Ukrainian Anticancer Institute in Vienna, Austria, have carried out clinical studies of Ukrain over a 10-year period on 206 patients with cancers at various stages of development. Total remissions were achieved even in cases of advanced metastatic cancer. The best success rate with Ukrain (93%) was achieved with cancer patients starting treatment at the earliest stage of tumor development (no metastasis). For those starting therapy in stage II (minimal metastasis), the success rate was 72%, and for those in stage III (advanced metastatic cancer), the success rate was 30%.

ety of cancers;<sup>119</sup> it consistently increases the number of T helper cells, which coordinate key immune-related activities. At the same time, Ukrain alters the oxygen consumption of cancer cells in an irreversible manner by increasing the oxygen (O<sub>2</sub>) consumption in both normal and malignant cells. In normal cells, the O<sub>2</sub> consumption rate then stabilizes within 15 minutes; in cancer cells, however, O<sub>2</sub> consumption drops down to zero.<sup>119</sup> Since the cancer cells stop "breathing" (called cell respiration) at this point, after 15 minutes of Ukrain treatment, they die.

Ukrain also inhibits the synthesis of genetic material and protein in cancer cells, but not in normal, healthy cells.<sup>121</sup> This may account for the findings supporting Ukrain's ability to completely inhibit growth in 57 of 60 human cell lines representing cancers of the lung, colon, kidney, ovary, breast, and brain, as well as melanoma and leukemia.<sup>122</sup> (These are the same 60 cancer cell types the NCI uses to screen effective cancer medications and determine research funding eligibility.) Only 2 leukemia cell lines and one brain cancer cell line were not inhibited by Ukrain. At high concentrations (100 mcg per ml), however, Ukrain causes "100% growth inhibition" in all 60 human cancer lines.

Finally, Ukrain possesses a strong attraction (cytotoxic selectivity) for cancer cells, and when exposed to ultraviolet light, it glows. For these reasons, it can be used to determine whether a suspicious growth is malignant.<sup>124</sup>

## UREA

One of the natural by-products of protein digestion (nitrogen) is urea, a natural diuretic (which means it induces urination) compound which also shows strong antioxidant activity. Approximately 1 ounce of urea is excreted daily in human urine. Urine-derived products have been used in cancer treatment since the 1940s, although they remain controversial.

When given orally, urea reaches high enough concentrations in the liver to inhibit cancer growth. Specifically, urea appears to work against solid tumors by destabilizing components called fibrin stroma; it also works against the formation of new blood vessels in tumors.

Observations made over an 11-year period by the physicians Evangelos Danopoulos, professor at the Medical School of Athens University and a member of the governing board of the Hellenic Anticancer Institute, and his daughter Iphigenia Danopoulos, both of Athens, Greece, indicate substantial clinical benefits from using urea to treat liver cancer.<sup>125</sup> Significant healing responses were reported in 15 of 22 patients diagnosed with cancer that had metastasized to the liver.<sup>126</sup> Since the liver is the only organ that shows high concentrations of urea after oral administration—the substance is rapidly excreted via the kidneys—this therapy may not be effective against cancers other than those of the liver.

More specifically, in 1954, Dr. Danopoulos announced that urine had anticancer properties. He proposed that the active component was urea, a by-product of protein metabolism secreted by the liver and the main substance excreted in the urine. Dr. Danopoulos found that injections of a 50% urea solution directly into a mass of large, fast-growing tumors was effective, and that injections around the tumor site were even more effective.<sup>127</sup> The theory behind urea therapy is that it alters the chemistry of the cellular surfaces around malignant tumor cells, and thereby disrupts the processes necessary for uncontrolled cellular growth.<sup>128</sup> Dr. Danopoulos also reported that when 46 patients with large cancers around the eye received urea injections and surgical removal of the tumors, this combination therapy was effective for 100% of these patients.<sup>129</sup>

Dr. Danopoulos then found, in the 1970s, that oral administration of urea was effective against liver cancer. In a study of 18 patients who were

**Significant healing responses were reported in 15 of 22 patients diagnosed with cancer that had metastasized to the liver. Since the liver is the only organ that shows high concentrations of urea after oral administration—the substance is rapidly excreted via the kidneys—this therapy may not be effective against cancers other than those of the liver.**



Urea is available in powder form (in a formula with creatine monohydrate) from: Innovative Therapeutics, 2020 Franklin Street, Carlyle, IL 62231; tel: 888-688-9922 or 618-594-7712; fax: 618-594-7711.

## ICH MÖCHTE LEID LINDERN

Für Eltern kann nichts schrecklicher sein, als die Diagnose Krebs bei ihrem Kind hinzunehmen und dann noch zusehen zu müssen, wie dieses Kind vor seinem Tod den physischen, aber auch psychischen Belastungen einer Chemotherapie ausgesetzt wird. Um dies zu vermeiden, habe ich mir bereits vor Jahren vorgenommen, ein neues ungiftiges Präparat gegen Krebs zu entwickeln. Zirka 400 neue Verbindungen habe ich hergestellt und patentieren lassen – die wirkungsvollste davon habe ich nach meiner Heimat Ukrain genannt.

Eine von vielen Krankengeschichten hat mich besonders erschüttert: Der dreijährige Stefan Dan mit der Diagnose „Generalisierte Lymphangiomatose“ wurde 1995 von den Ärzten als austherapiert nach Hause geschickt. Um die Eltern zu „trösten“, wurde ihnen gesagt, daß ihr Stefan nie im Leben sprechen und laufen würde können. Nach zwei Jahren Ukrain-Therapie durch einen praktischen Arzt konnte das Kind sehr wohl sprechen und auch laufen. Unter Berufung auf gesetzwidrige Erlässe des Gesundheitsministeriums von 1986 bzw. 1994 wurden die Eltern anlässlich einer Kontrolluntersuchung im Spital unter Androhung von Strafen genötigt, die Therapie mit Ukrain abzubrechen, obwohl man keine andere Therapiemöglichkeit anbieten konnte. Der Tumor begann daraufhin zu wachsen und verursachte eine Kompression des Rückenmarks. Stefan – mittlerweile acht Jahre alt – wurde operiert. Trotz des operativen Eingriffes hat sich der Zustand des kleinen Patienten ständig verschlechtert, so daß er an ein Beatmungsgerät angeschlossen werden mußte. Es trat eine Querschnittlähmung auf. In diesem Zustand wurde das Kind in häusliche Pflege entlassen. Um seine Schmerzen zu lindern, mußte man ihm vier-

mal pro Tag Morphinum verabreichen, seine Atmung mußte durch einen Heimrespirator unterstützt werden. Jetzt empfehlen die Ärzte den Eltern, sich doch wieder der Ukrain-Therapie zuzuwenden. Der Zustand des Kindes konnte durch die Ukrain-Therapie zwar verbessert werden. Stefan kann sprechen, wird aber nie mehr gehen können.

Die kurze Zusammenfassung dieser Krankengeschichte am Ende des Buches (Seite 185 ff.) dokumentiert das traurige Schicksal des kleinen Patienten, der wegen der fahrlässigen Unterbindung der Ukrain-Therapie sein Leben lang gelähmt bleiben wird.


Darf man weiterhin tatenlos zusehen, wie krebskranken Kindern und Erwachsenen, die von der Schulmedizin aufgegeben sind, eine erfolgversprechende Therapie vorenthalten wird? Da Ukrain aus zwei bereits zugelassenen Ausgangsstoffen hergestellt wird und nachweislich hundertmal weniger toxisch als diese Ausgangsstoffe, hingegen sehr wirksam ist, habe ich 1976 in Österreich den Antrag gestellt, das Präparat für austherapierte Fälle zuzulassen. Statt meinem Antrag stattzugeben und mit dem Präparat Betroffenen zu helfen, haben die zuständigen Gesundheitsbehörden und Landesvertretungen alles getan, um die Anwendung und Verbreitung des Medikamentes in Österreich als Ursprungsland – und damit auch automatisch im Ausland – zu verhindern.

In diesem Buch wird die Wirksamkeit von Ukrain anhand gut dokumentierter Fälle vorgestellt, ebenso wie die permanenten Versuche, mich in meiner Arbeit zu behindern. Die einzige Förderung, die ich in Österreich je bekommen habe, verdanke ich der Zivilcourage des früheren Chefs der Forschungssektion im Wissenschaftsministerium, Dr. Norbert Rozsenich. Viele Leser früherer Ausgaben von „Wer hat Angst vor Ukrain?“ drückten mir ihre Erschütterung über den Inhalt aus. Aber jahrelang das Leid der Betroffenen mit ansehen zu müssen, war noch schlimmer. In Österreich erkrankten jährlich 200 Kinder



an Krebs. Einigen konnte dank Ukrain geholfen werden. Selbst wenn ich nur einem einzigen Kind hätte helfen können, wie dem kleinen Stefan, wäre das ein Grund, nicht zu kapitulieren. Ich gebe nicht auf!

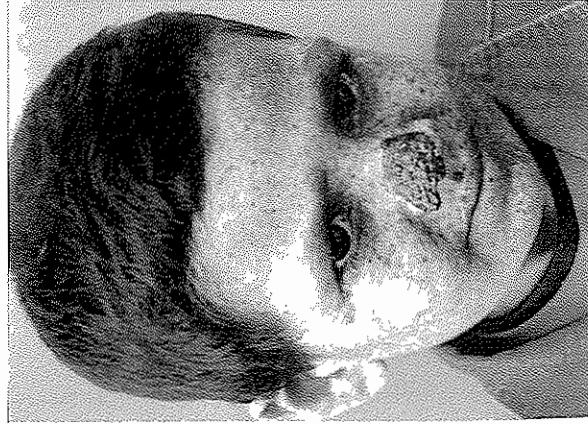Wien, im April 2004

A handwritten signature in black ink, appearing to read 'Wassil Nowicky'. The signature is written in a cursive, somewhat stylized script with a long, sweeping underline that extends to the right.

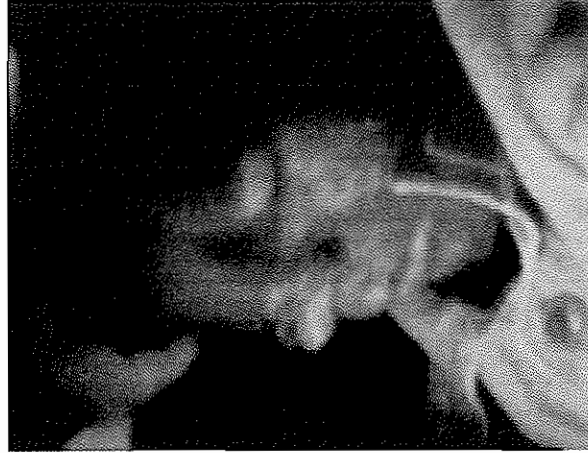
Wassil Nowicky

# Ukrain (NSC-631570) in xeroderma pigmentosum

**Patient S.S., an eight year old boy, was presented with an ulcering lesion of the nose. As he was 10 month old, xeroderma pigmentosum was diagnosed.** (Patients with xeroderma pigmentosum have a severe sensitivity to all sources of ultraviolet radiation, especially sunlight and develop serious sunburns with onset of poikiloderma in the light-exposed skin. There is a wide range of symptoms: blindness and deafness, blistering or freckling on minimal sun exposure, developmental disabilities, dwarfism and hypergonadism, increased skin and eye cancers, and mental retardation. Squamous cell carcinomas, basal cell carcinomas and malignant melanomas already appear in childhood. The majority of patients die before reaching adulthood because of metastases of malignant melanoma). **Until the age of three years the number of skin lesions increased considerably. In May 2002 skin cancer (squamous cell carcinoma) at the nose was diagnosed, T4NXM0, histologically verified. From May till June 2002 three cycles of chemotherapy were administered (cyclophosphamide, vincristine, vinblastine). The therapy failed and the tumors grew up. Clinical investigation in April 2004 revealed deforming malignant melanoma of the nose with invasion into the cartilage of nasal septum, measuring 3x3 cm. On 20 May 2004 the therapy with Ukrain was started, 5 mg intravenously twice a week, up to a total dose of 85 mg. One month after the last administration of Ukrain a complete regression of the tumor was revealed. The skin defect was partially replaced with connective tissue. Xeroderma skin lesions improved throughout the body.**



Patient S.S. before the therapy with Ukrain. Deforming invasive malignant melanoma of the nose. April 2004.



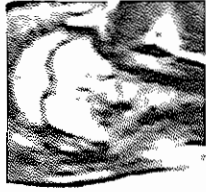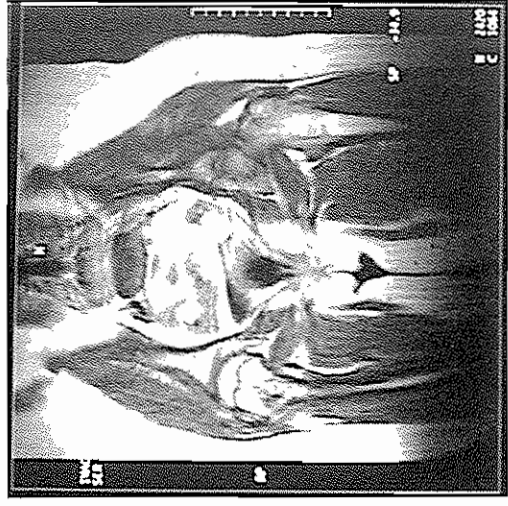
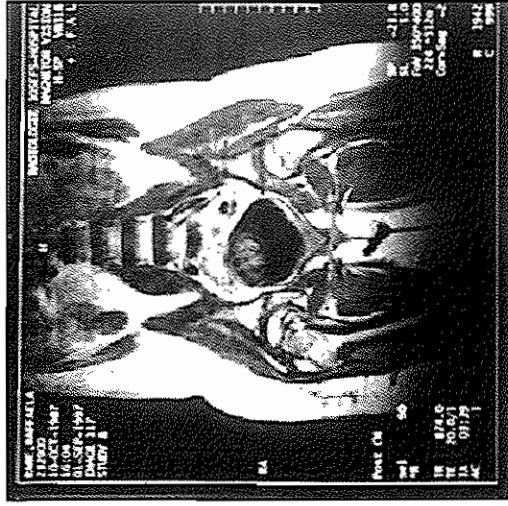
Autofluorescence of NSC-631570 at the melanoma area under UV-light during the first intravenous injection. May 2004.



Patient S.S. in December 2004. Complete regression of the tumor, with connective tissue substitution.

Nowicky Pharma, 2006

**Ewing's sarcoma, first diagnosed 18.3.1996, histologically verified; tumour resistant to both chemotherapy and radiotherapy. UKRAIN therapy started on 13 October 1997 [115].**



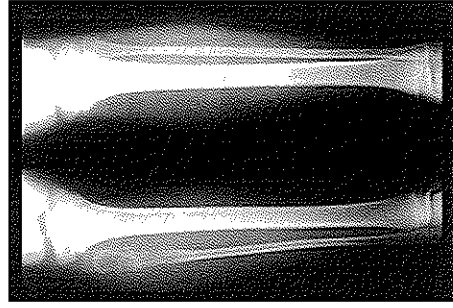
1.9.1997

1.2.2001

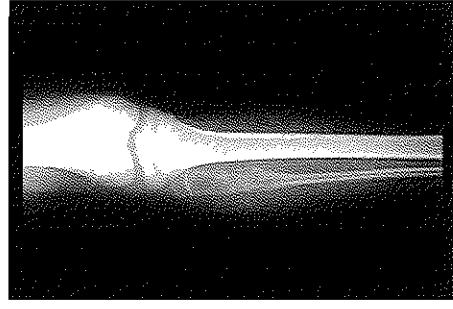
1.2.2001

The patient, a 10 year-old girl, was treated in the high-risk arm of the EICESS 92 study. MRI examination of the pelvic region on 1.9.1997 showed progression in the cystic-edematous process. She was then treated with combined Ukrain and local hyperthermia therapy. The therapy series consisted of 15 mg Ukrain in an infusion with 250 ml glucose and 5 g vitamin C, followed by local hyperthermia treatment. Treatment was administered every second day up to a total of 10 therapy sessions. MRI examination on 8.1.1998 showed no progression of the tumour. Subsequent therapy cycles caused regression of the tumour (see MRI on 15.6.1999 and 1.2.2000). MRI on 1.2.2001: Cystic residual defect in right femur, as observed in previous examinations. No sign of a relapse or of metastases.

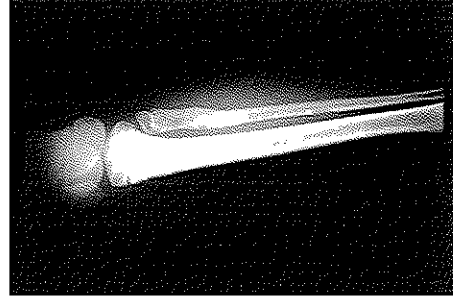
**Ewing's sarcoma, first diagnosed 22.11.1983, histologically verified, tumour resistant both to chemotherapy and radiotherapy. UKRAIN therapy started on 21 January 1984 [28].**



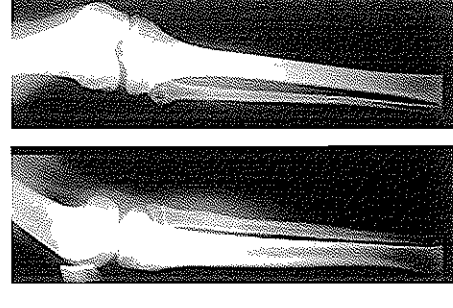
22.11.1983



18.1.1984



14.12.1984



31.10.1990

A 9 year-old girl had felt marked pain below the right knee joint in November 1983 following a slight injury. X-ray revealed Ewing's sarcoma in the proximal portion of the right fibula. Hospital treatment included chemotherapy and cobalt therapy. X-rays confirmed that the patient's tumour had not responded to radiation or chemotherapy and the tumour mass increased rapidly. One month after the end of chemotherapy, UKRAIN treatment was started at a dose of 5 mg i.m. for a total of 10 injections, combined with regional deep hyperthermia. The first series of UKRAIN therapy included three identical courses with a two-week pause between them. Six series of UKRAIN treatment were administered over the course of one year. Repeated x-rays showed reduction of the tumour mass.

## TREATMENT OF GENERALIZED LYMPHANGIOMATOSIS WITH UKRAIN: A CASE REPORT

LANGER A., ZAHRIYCHUK O., HODYSH Y.

Ukrainian Anti-Cancer Institute, Vienna, Austria.

**Summary:** *We report on the first case of the use of Ukrain in the treatment of generalized lymphangiomas complicated with decubital ulcers in a child. Lymphangiomas presented in various parts of the body. Despite a highly unfavorable prognosis, the therapy with Ukrain proved to be of significant value, benefiting the general development of the young patient and ameliorating the course of the disease.*

### Introduction

Lymphangioma, or cystic hygroma, or lymphatic malformation, is a localized or generalized growth of anomalous lymphatic channels and cysts (1). These are relatively rare congenital malformations and make up approximately 6% of all benign lesions in children (2). Lymphatic anomalies occur in both sexes with equal frequency and in all races (3). Seventy to 90 percent are clinically evident at birth or become noticeable within the first two years of life (4). Lymphangiomas are usually found in the head and neck region. The axilla and mediastinum are the second most frequent location sites, and may be encountered as primary

sites or as the extension of a neck lymphangioma. The retroperitoneum and the extremities are rare sites for this tumor.

There are three main groups of lymphatic malformations. The first and most common group consists of hypoplasia or aplasia of lymph vessels and nodes leading to inadequate clearance and presenting as lymphedema. The second group consists of disorders of the circulation of chyle. The third group, presenting in our patient, consists of solitary or multiple cystic lymphatic malformations. Multicystic lymphatic malformations can be micro- or macrocystic (4). Transillumination is highly characteristic of macrocystic lymphangiomas (5).

The characteristic history of a lymphatic malformation is enlargement commensurate with the child's growth, with intermittent periods of swelling due to hemorrhage into the lesion.

Address for correspondence: Oleh Zahriychuk, Ukrainian Anti-Cancer Institute, Margaretenstr. 7, A-1040 Vienna, Austria.  
E-mail zahriychuk@yahoo.com

Lymphangiomas may cause marked disfigurement; recurrent infections; respiratory obstructions; malocclusion; and dysphagia, dysphonia and dysarthria, as a result of the infiltration and compression of neighboring structures.

Lymphangiomas may occur in association with venous malformation. Pure venous malformations can occur in any tissue in the body and can widely infiltrate skin, muscles, joints and, sometimes, bones. Combined lymphatic-venous lesions are often associated with skeletal elongation and hypertrophy. There was no evidence in our patient of bone involvement with the malformation, which was consistent with the main element being lymphatic.

We report on the treatment of generalized lymphangiomas in a child with the drug Ukrain. Lymphangiomas presented in various parts of the body and the course of the disease was unfavorable.

### Case report

The patient, S.D., male, was born on September 22, 1992, at 7 months of gestation, as the fourth child in a family. No congenital disorders had been observed previously in the family, and the mother subsequently gave birth to three more children without any congenital problems being observed.

A large soft tissue tumor on the left dorsal thorax wall was observed following delivery. A computed tomography (CT) scan carried out the day after delivery revealed a paravertebral lymphangioma in the left posterior mediastinum, and another in the area of the dorsal body wall. Clear communication between the tumors could not be seen on the CT. Both tumors were clearly separated from the spinal canal. A magnetic resonance imaging (MRI) scan performed on October 1, 1992, showed that the tumors were lymphangiomas, or cystic hygromas. The second paravertebral tumor had reached the arch of the aorta in the cranial direction.

During the first month of life, the swelling on the thoracic wall expanded and a skin infection occurred, following which the patient was admitted to the hospital. On admission, the patient was in good general condition, weight gain was adequate, and spontaneous motor activity was well developed. As before, there was a large, soft, fluctuating, brownish, blurred tumor.

On November 11, 1992, partial resection of the extrathoracic tumor was carried out. Under histological examination, lymphangiomas was verified and a residual tumor was confirmed. Wound healing proceeded very slowly and was complicated by relapsing infections treated with antibiotics.

An ultrasound examination carried out on April 20, 1993, revealed no free fluid in the abdomen and a small pleural effusion on the left side. Lymphangioma in the left inguinal area and bilateral scrotal hydrocele were diagnosed.

In June 1993, bilateral otitis media with purulent inflammation and perforation occurred and was treated with antibiotics.

A CT scan performed on November 9, 1993, revealed substantial growth of the existing tumors compared with September 1992, with partially intrathoracic and partially extrathoracic soft tissue tumors. The intrathoracic tumor surrounded the descending aorta and left clavicular artery. An MRI scan carried out on November 19, 1993, showed extended infiltration of the tumor into the spinal canal from Th1 to Th8, with maximum infiltration in Th4 to Th7; right upper dorsal lobar atelectasis was also revealed.

A CT scan performed on January 27, 1994, revealed clear extension of the extrathoracic tumor while the intrathoracic and spinal components remained unchanged. Neurological examination revealed an incomplete paraplegia, most likely L5-S1. Physical and neurosurgical examination revealed that due to the substantial tumor growth, the tumors were inoperable. Therapy with alpha-interferon (IFN)-2a (Roferon®-A3, Hoffmann-La Roche AG, Grenzach, Germany), 3

billion U/m<sup>2</sup>/day, s.c., was initiated. During IFN therapy, infections occurred frequently and were treated with antibiotics. Echocardiography revealed clear diminished left ventricular function, with the superior vena cava and vena azygos significantly dilated. Digitalis therapy with digoxin 0.125 mg p.o. (Lanicor<sup>®</sup>; Boehringer Mannheim, Mannheim, Germany) was initiated.

An ultrasound examination on March 8, 1994, revealed diffuse expansion of the tumor in the left thoracic area, and an MRI scan on April 8, 1994, showed no changes in the spinal canal.

Unfortunately, IFN therapy did not have any impact on the course of the disease and was discontinued after 4 months. No further therapy other than palliative care could be recommended by the physicians in charge of the case. The patient's general condition was extremely poor, since he could

neither speak nor move. He was discharged from the hospital to home care with a very unfavorable prognosis, with the parents being told that the child would never walk or speak.

In April 1995 therapy with Ukrain (Nowicky Pharma, Vienna, Austria) was started on an outpatient basis, initially at a dose of 10 mg, i.v., on alternate days, and later at 5 mg, i.v., twice a week. Informed consent of the parents was received before the start of therapy. A letter from the Drug Council of the Austrian Ministry of Health, Sport and Consumer Protection dated June 23, 1993, approved the use of Ukrain on an outpatient basis. The patient's state improved gradually.

On July 17, August 22 and September 19, 1995, three punctures of intra-abdominal cystic lymphangiomas were performed, with 3.5, 0.5 and 1 l of hemorrhagic fluid drained, respectively (Fig. 1).

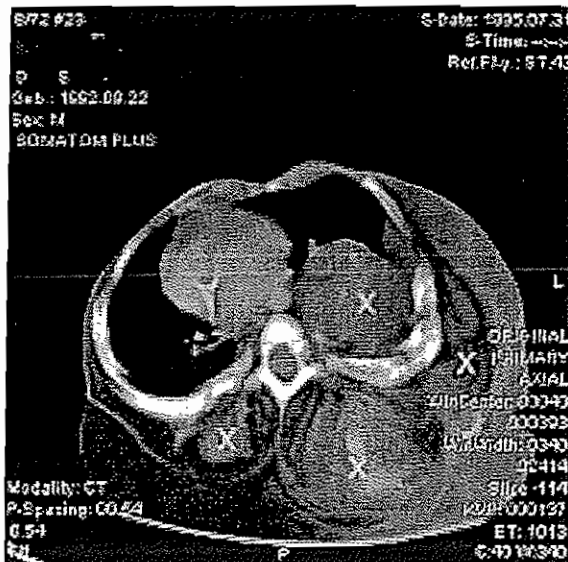


Fig. 1 Multiple lymphatic malformations (x) and a chest wall deformation are clearly seen under computed tomography scan, July 31, 1995

In November 1995, after a total dose of 220 mg Ukrain had been administered, the patient began to move, and in December 1995, after a total administered dose of 260 mg, he began to speak his first words. By 1996, the patient could stand, and by 1997 the patient could both speak and walk.

However, on the basis of Decree GZ 21.405/1117-III/A/8/93 of February 25, 1994, of the Austrian Ministry of Health, Sport and Consumer Protection, Ukrain therapy was discontinued.

On October 9, 1998, partial resection of a left intrascrotal lymphangioma and a left thoracic lymphangioma with subsequent drainage were performed.

At the beginning of 2000, the patient's condition worsened. Tumor progression caused spinal cord compression, and paraplegia occurred. On January 15 the patient could no longer walk. On March 23, 2000, an extended resection of a thoracolumbal lymphangioma on the back and complex grafting were performed in the Department of Pediatric Surgery at the Donauspital in Vienna. The body weight before surgery was 22 kg and the weight of the ablated tumor was 10 kg. Following surgery the patient remained in a coma for 6 weeks. The patient was on assisted ventilation due to the weakness of the respiratory muscles, and morphine was administered four times a day due to severe pain.

In August 2000, two decubital ulcers developed over the right trochanter and the right shoulder blade. Paraparesis extended to Th5. The decubital ulcers were treated surgically. After discharge from the hospital, a portable ventilator had to be used and morphine administration continued at home. The patient's state seemed hopeless to the hospital physicians (Donauspital, Vienna) and they recommended resumption of treatment with Ukrain.

Therapy with Ukrain 5 mg, i.v., twice a week was resumed on an outpatient basis. Additionally, topical application of Ukrain in gauze compresses was begun. After 3 months of treatment, the patient no longer

complained of pain, and morphine administration was discontinued. After 2 years of therapy, the ventilator was no longer needed. The decubital ulcers healed without skin defects.

## Discussion

Treatment options for lymphangioma include surgery and sclerotherapy. Surgical treatment is challenging. Complete excision is often impossible due to the risk of damage to vital or functionally important surrounding structures. In addition, the cosmetic outcome after such radical surgery may be unacceptable, especially in children. Generally, the results of surgical treatment are currently assessed as unsatisfactory with a high incidence of recurrence and nerve damage. The case presently reported also demonstrates the high risk which accompanies surgical treatment of lymphangioma.

Several other treatment options have been used to treat lymphangioma. These include laser therapy (6); IFN-alpha (7); and various intralesional sclerosing agents, e.g., boiling water, quinine, sodium morrhuate, urethane, iodine tincture, nitromin, steroids, hypertonic saline and ethanol. While little success has been reported using these options, various side effects have been observed (8). In the present case described, 60% dextrose solution was used for intralesional sclerosing therapy with little success. OK-432 (Picibanil) and bleomycin are currently the most frequently used sclerosing agents, giving quite good results (1, 9-13). However, in patients who have undergone prior surgery, the success rate is significantly lower than in primary cases due to the obliteration of communications between cysts following the earlier therapy (9).

This is the first case report of the use of the anti-cancer drug Ukrain in the treatment of a benign multiple tumor. Ukrain is known for its low toxicity, and its



safety was confirmed in this case. Although the course of the disease was complicated by major psychomotoric and developmental problems, the use of Ukrain was of clear benefit and improved both the general development of the young patient and the course of the disease.

The positive dynamics of the disease following the administration of Ukrain, the recurrence of disease after discontinuation of Ukrain, and the improvement in status after resumption of Ukrain therapy, all indicate that the therapeutic benefit was not a coincidence, but rather the result of the specific activity of Ukrain. The period in which administration had to be discontinued for nonclinical reasons must be regarded as a lost opportunity to heal a growing child.

## References

- (1) Laranne J., Keski-Nisula L., Rautio R., Rautiainen M., Aitaksinen M. OK-432 (Picibanil) therapy for lymphangiomas in children. *Eur. Arch. Otorhinolaryngol.*, **259**, 274, 2002.
- (2) Orvidas U., Kasperbauer J.L. Pediatric lymphangiomas of the head and neck. *Ann. Otol. Rhinol. Laryngol.*, **109**, 411, 2000.
- (3) Fishman S., Mulliken J. Hemangiomas and vascular malformations of infancy and childhood. *Pediatr. Clin. N. Am.*, **40**, 1177, 1993.
- (4) Young A.E. Lymphatic malformations. In: Mulliken J.B., Young A.E. (Eds.) "Vascular Birthmarks: Hemangiomas and Vascular Malformations." WB Saunders, Philadelphia, 1988, pp. 215-227.
- (5) Makkat H.S., Frieden I.J. Transillumination of a cystic lymphatic malformation. *N. Engl. J. Med.*, **349**, 19, 2003.
- (6) Eyrich G.K., Bruder E., Hilliker P., et al. Temperature mapping of magnetic resonance guided laser interstitial thermal therapy (LITT) in lymphangiomas of the head and neck. *Lasers Surg. Med.*, **26**, 467, 2000.
- (7) Reinhardt M.A., Nelson S.C., Sencer S.F., Bostrom B.C., Kurachek S.C., Nesb M.E. Treatment of childhood lymphangiomas with interferon-alpha. *J. Pediatr. Hematol. Oncol.*, **19**, 732, 2000.
- (8) Smith R.J.H., Burke D.K., Sato Y., Poust R.I., Kimura K., Bauman N.M. OK-432 therapy for lymphangiomas. *Arch. Otolaryngol. Head Neck Surg.*, **122**, 1195, 1996.
- (9) Greinwald J.H., Burke D.K., Sato Y., et al. Treatment of lymphangiomas in children: an update of Picibanil (OK-432) sclerotherapy. *Otolaryngol. Head Neck Surg.*, **121**, 381, 1999.
- (10) Ogata S., Tsuto T., Nakamura K., Deguchi E., Iwai N. OK-432 therapy in 64 patients with lymphangioma. *J. Pediatr. Surg.*, **29**, 784, 1994.
- (11) Okada A., Kubota A., Fukuzawa M., Imuta K., Kamata S. Injection of bleomycin as a primary therapy of cystic lymphangioma. *J. Pediatr. Surg.*, **27**, 440, 1992.
- (12) Sanlıtalp I., Karnak I., Tanyel F.C., Senocak M.E., Büyükpamukçu N. Sclerotherapy for lymphangioma in children. *Int. J. Pediatr. Otorhinolaryngol.*, **67**, 795, 2003.
- (13) Claesson G., Kuylenstierna R. OK-432 therapy for lymphatic malformation in 32 patients (28 children). *Int. J. Pediatr. Otorhinolaryngol.*, **65**, 1, 2002.

## CLINICAL IMPROVEMENT OF A PATIENT WITH XERODERMA PIGMENTOSUM AFTER TREATMENT WITH UKRAIN: A CASE REPORT

ASCHHOFF B.

Villa Medica Clinic, Edenkoben, Germany.

**Summary:** *Xeroderma pigmentosum (XP) is a rare genetic defect of the skin DNA repair system. The author presents a case report of a patient with XP, successfully treated with Ukrain. Future studies should be performed to define the best therapeutical schedules of Ukrain in the treatment of this disease.*

### Introduction

Xeroderma pigmentosum (XP) was first described in 1874 by Hebra and Kaposi (1). In 1882, Kaposi coined the term for the condition, referring to its characteristic dry, pigmented skin. XP is a rare disorder transmitted in an autosomal recessive manner. The prevalence in Europe and the United States is approximately one case per 250,000 population, and in Japan, one case per 40,000 population. There are fewer than 1,000 known cases of XP worldwide. Cases of XP are reported in all races with equal distribution between males and females (2).

The disease manifests at age one or two years. Patients with XP have a severe sensitivity to all sources of ultraviolet (UV) radiation, especially sunlight, and they develop serious sunburns with onset of poikiloderma in light-exposed skin. The range of symptoms is wide: blindness and deafness, blistering or freckling on minimal sun exposure, developmental disabilities, dwarfism and hypergonadism, increased skin and eye cancers, and mental retardation (3). Squamous cell carcinomas, basal cell carcinomas and malignant melanomas can appear in childhood. The majority of patients die before reaching adulthood because of metastases.

XP is based on a genetic defect in the DNA repair system. This defect is in nucleotide excision repair (NER), leading to deficient repair of DNA damaged by UV radiation (4). Seven XP repair genes, XP-A through XP-G, have been identified. These genes play key

---

*Address for correspondence.* Dr. B. Aschhoff, Villa Medica Clinic, Klosterstrasse 179, 67480 Edenkoben, Germany  
Tel: +49 6323 8020 Fax: +49 6323 7943  
E-mail: info@villamedica.de

roles in global genome (GG)-NER and transition-coupled (TC)-NER. Both forms of NER include a damage-sensing phase, performed in GG-NER by the product of the XP-C gene complexed to another factor. In addition, the XP-A gene product has been reported to have an affinity for damaged DNA. Therefore, it is likely that XP-A also plays a role in the damage-sensing phase (5).

Genetically, XP is divided into seven complementation groups (XP-A to XP-G) corresponding to defects in the corresponding gene products of XP-A to XP-G genes and the XP variants (XP-V). These entities occur with different frequencies (e.g., XP-A is relatively common and XP-E is fairly rare), and they differ with respect to disease severity (e.g., XP-G is severe and XP-F is mild) and clinical features. Group XP-C is the most common form in Europe and North America, while group XP-A is the most common form found in Japan (6).

Diagnostically, assignment to the specific complementation group is made according to the fusioning of XP fibroblasts (5, 7). Differential diagnosis must distinguish XP from other so-called DNA-repair-deficiency syndromes, such as Cockayne syndrome and trichothiodystrophy (1).

In addition to the defects in the repair genes, UV-B radiation also has immunosuppressive effects that may be involved in the pathogenesis of XP. Although typical symptoms of immune deficiency, such as multiple infections, are not usually observed in patients with XP, several immunologic abnormalities have been described in the skin of patients with XP. Clinical studies of the skin of patients with XP indicate prominent depletion of Langerhans' cells induced by UV radiation. Various other defects in cell-mediated immunity have been reported in XP. These defects include impaired cutaneous responses to recall antigens, decreased circulating T-helper cells-to-suppressor cells ratio, impaired lymphocyte proliferative responses to mitogen, impaired production of inter-

feron in lymphocytes, and reduced natural killer cell activity (8).

In XP, DNA damage is cumulative and irreversible, and treatment is limited to avoidance of exposure to UV radiation by staying indoors with sunlight blocked out and the use of protective clothing, sunscreens, and eyeglasses (9). There is no cure for XP and each advance in treatment should be discussed. We present a case of XP successfully treated with Ukrain (NSC 631570).

#### Case report

The patient, born in 1985, was diagnosed with XP at an early age. The short summary of clinical course below shows the progression of disease and total failure of palliative treatment.

In August 1996, the skin of the dorsum of the nose, the upper lip, the front parts of the cheeks and the right interior eyelid was ablated and substitutive dermatoplasty was performed.

In January 1997, the skin of the whole forehead, the superior and interior eyelid, and the nasolabial region was ablated with subsequent substitutive dermatoplasty. Six basalomas, four squamous cell carcinomas, five precancerous keratosis, two regions of eczema and one nevoid lentigo were also ablated.

In October 1997, squamous cell carcinoma of the left part of the chin and pyogenic granuloma of the right interior eyelid were ablated, and total substitutive dermatoplasty of the right superior and interior eyelid and periorbital region, and implantation of tissue expanders (300 ml) were performed.

In April 1998, skin expander explantation was carried out, and different carcinomas, basalomas and precancerous lesions in the face region were ablated, followed by substitutive dermatoplasty of the chin and nasolabial region.

In February 1999, a basalioma-like growing squamous cell carcinoma of the right inferior eyelid was resected and followed by plastic cheek reconstruction and conjunctive mobilization, excision of the left cheek, right eyebrow and right supraclavicular region basaliomas was performed, and postoperative skin defects were corrected plastically.

In August 1999, a malignant melanoma (1.20 mm thick; level IV, stage Ib; pT 2) in the region of the right hip was ablated, along with retroauricular (right) and helix (left) squamous cell carcinomas.

In September 1999, squamous cell carcinomas of the concha (the region of the left helix) and the throat, nevoid lentigo of the right hip and basalioma of the right popliteal surface were ablated.

In April 2000, diagnostic curettage of the basalioma and actinic keratosis of the throat took place, along with myxoid dermatofibroma of the right dorsum manus.

In August 2000, multiple basaliomas of the right and left ears, and of the right nostril and right cheek, along with squamous cell carcinoma of the right cheek were resected; an operation was performed to remove Bowen's disease on the right hand and under the costal margin, and a melanoma on the left cheek was excised.

All these diagnostic and therapeutic interventions were performed at different clinics, and consisted only of symptomatic tumor ablation with no attempts made to avoid new cancer lesions.

From September 2001 until the present date, the patient has been receiving Ukrain (Nowicky Pharma, Vienna, Austria) therapy: four ampoules a week intravenously, with topical Ukrain administration (application of 1 mg/ml of the drug solution with lesion bandage. One course of Ukrain lasts 2 months: 160 mg of Ukrain per course, with treatment interrupted for the following 2 months.

## **Results**

Prior to the start of Ukrain treatment, more than 50 operations had been performed with the aim of

skin tumor ablation. Since the start of Ukrain treatment, the only operations needed were to excise the following tumors: in July 2002, three little basaliomas and in March 2003 two basaliomas. Prior to Ukrain treatment, six to seven operations were performed. It is noteworthy that no malignant tumor has occurred since the start of Ukrain treatment.

## **Discussion**

XP is usually detected at age one or two years. Individuals with this disease develop multiple cutaneous neoplasms at a young age. Two important causes of mortality are metastatic malignant melanoma and squamous cell carcinoma. Patients younger than 20 years have a 1,000-fold increase in the incidence of nonmelanoma skin cancer and melanoma. The mean skin cancer patient age is eight years in patients with XP, compared to 60 years in the healthy population (3, 10).

As there is no cure for the genetic disorder XP, the main goal of treatment is the prompt and complete removal of skin cancers by skin surgeons.

The treatment goal is to protect the patient from sunlight. Oral retinoids have been shown to decrease the incidence of skin cancer in patients with XP. This therapy is limited by dose-related, irreversible calcification of ligaments and tendons (4, 11). Complete excision of the malignancies associated with XP should be performed. The goals of pharmacotherapy are to reduce morbidity and to prevent complications (12). Fewer than 40% of patients survive beyond age 20 years. Individuals with milder disease may survive beyond middle age. The prominent results of treatment with Ukrain can be explained due to both its direct antineoplastic activity and its indirect immunomodulation. No side effects were observed during the treatment. Future studies should make clear the possible mechanisms of the phenomenon observed.

Aschhoff B.

## References

- (1) Hebra F., Kaposi M. *On diseases of the skin including exanthamata*. New Sydenham Soc., 61, 252, 1874
- (2) Norgauer J., Idzko M., Panlther E., Hellstern O., Herouy Y. *Xeroderma pigmentosum*. *Eur. J. Dermatol.*, 13(1), 4, 2003.
- (3) Kraemer K.H., Lee M.M., Scotto J. *Xeroderma pigmentosum Cutaneous, ocular, and neurologic abnormalities in 830 published cases*. *Arch. Dermatol.*, 123(2), 241, 1987.
- (4) de Laat W.L., Jaspers N.G., Hoijmakers J.H. *Molecular mechanism of nucleotide excision repair*. *Genes Dev.*, 13(7), 768, 1999
- (5) Fackel N., Dertinger H., Wolf G.K. *Induction of sister chromatid exchanges in fibroblasts from normal donors and from patients with xeroderma pigmentosum after combined treatment with ultraviolet radiation and modulated low frequency electric currents*. *Eur. J. Dermatol.*, 8(7), 483, 1998
- (6) Busch D. *Gene therapy and protein therapy*. *Cancer Res.*, 58, 4402, 1998
- (7) Alapetite C., Benoit A., Moustacchi E., Sarasin A. *The comet assay as a repair test for prenatal diagnosis of Xeroderma pigmentosum and trichothiodystrophy*. *J. Invest. Dermatol.*, 108(2), 154, 1997
- (8) Dumaz H., Drougard C., Quillet X., et al. *Recovery of the normal p53 response after UV treatment in DNA repair-deficient fibroblasts by retroviral-mediated correction with the XPD gene*. *Carcinogenesis*, 19(9), 1701, 1998.
- (9) Elmets C.A., Anderson C.Y. *Sunscreens and photoarcinogenesis: An objective assessment*. *Photochem. Photobiol.*, 63(4), 435, 1996
- (10) English J.S., Swerdlow A.J. *The risk of malignant melanoma, internal malignancy and mortality in xeroderma pigmentosum patients*. *Br. J. Dermatol.*, 117(4), 457, 1987.
- (11) Kraemer K.H., DiGiovanna J.J., Moshell A.N., et al. *Prevention of skin cancer in xeroderma pigmentosum with the use of oral isotretinoin*. *N. Engl. J. Med.*, 318(25), 1633, 1988
- (12) Yarosh D.B., O'Connor A., Alas L., et al. *Photoprotection by topical DNA repair enzymes. Molecular correlates of clinical studies*. *Photochem. Photobiol.*, 69(2), 136, 1999

**UKRAIN, A THIOPHOSPHORIC ACID DERIVATIVE OF ALKALOIDS OF *CHELIDONIUM MAJUS L.*, IS EFFECTIVE IN THE TREATMENT OF RECURRENT BRONCHOPULMONARY PATHOLOGY IN CHILDREN FROM AREAS CONTAMINATED AFTER THE CHERNOBYL ACCIDENT**

**ZAHRIYCHUK O.**

Ukrainian Anti-Cancer Institute, Vienna, Austria.

**Summary:** *A total of 38 children, drawn from areas contaminated after the Chernobyl accident and suffering from recurrent bronchopulmonary pathology, were included in the study. To ascertain the effects of Ukrain, an anticancer and immunomodulating drug, it was administered intravenously at a dose of 5 mg twice a week, up to a total dose of 35 mg. The control group included 10 children with the same pathology who received standard anti-inflammatory therapy. Compared with the control group, the group treated with Ukrain showed marked anti-inflammatory activity, rapid decrease in white blood cell count and blood sedimentation rate. The strong immunomodulatory effect of Ukrain was indicated through the improvement in specific humoral and cellular immunity: increases in the immunoglobulin G (IgG) level, the phagocytic activity of neutrophils, the number of total lymphocytes, T-lymphocytes and T-helpers, and the T-helpers/suppressors ratio. In view of the positive results of this pilot study and the great importance of preventive and clinical investigation of this problem given the widespread distribution of nuclear power plants and of nuclear military equipment, further studies devoted to the impact of Ukrain on children with immune disorders from contaminated areas would be interesting and could lead to positive results.*

**Introduction**

The health of a child can be affected by many environmental factors. Nowadays, one of the most

serious and sometimes fatal influences is ionizing radiation, which can lead to the development of cancer and other diseases, mental retardation and, in conjunction with other concomitant circumstances, psychic and social disadaptation. Ionizing radiation is one of the main factors defining the health status of adolescents in Ukraine as one of the countries most profoundly affected by the Chernobyl disaster.

*Address for correspondence:* Oleh Zahriychuk, Ukrainian Anti-Cancer Institute, Margaretenstr. 7, 1040 Vienna, Austria. E-mail: zahriychuk@yahoo.com

On April 26, 1986, the Chernobyl nuclear power station suffered an accident that led to the prolonged release of large amounts of radioactive substances into the atmosphere. Specific features of the incident favored a widespread distribution of radioactivity throughout the northern hemisphere, especially across Europe. Contributing factors were varying meteorological conditions and wind regimes during the period of release. Radioactivity transported by multiple plumes from Chernobyl was measured not only in northern and southern Europe, but also in Canada, Japan and the United States. Only the southern hemisphere remained free of contamination. Released radioactive isotopes ( $^{133}\text{Xe}$ ,  $^{131}\text{I}$ ,  $^{134}\text{Cs}$ ,  $^{137}\text{Cs}$ ,  $^{132}\text{Te}$ ,  $^{89}\text{Sr}$ ,  $^{90}\text{Sr}$ ,  $^{140}\text{Ba}$ ,  $^{95}\text{Zr}$ , etc.) in the form of gases, aerosols and finely fragmented nuclear fuel particles had an extremely detrimental agricultural and environmental impact. Currently, the frequency of late health stochastic effects of the radiation is the subject of numerous studies (1).

A large number of reviews and clinical and epidemiological investigations have been devoted to defining the precise impact of the Chernobyl accident on the health of children from contaminated territories. Special attention has been paid to possible increases in cancer diseases, in accordance with the data that children are much more radiosensitive than adults: a 1-year-old infant has a 10- to 15-fold greater risk than a 50-year-old adult of developing a malignancy from the same dose of radiation (2).

One type of radiation-induced malignant disease in children, with a minimum latency period of less than 10 years, is thyroid cancer (3). Because of relatively high thyroid doses (up to a few grays) resulting from inhaled and ingested radioiodine, including  $^{131}\text{I}$  and a few short-lived iodine-isotopes, it was not really surprising that childhood thyroid cancer was the first tumor type to show signs of marked increase in many areas in the vicinity of Chernobyl. This increase began in 1990, and was first observed in Belarus (4-

6). In relative terms, the increase was pronounced and has been over 100-fold in some areas. The initial reports met with considerable skepticism in some scientific quarters (7), and it was pointed out that many types of thyroid carcinoma were clinically indolent, and that any active search for such tumors might greatly influence the number found. Further criticism was based on the apparent early finding that an increase was observed only in Belarus and not in other areas which had experienced relatively high fallout. Later, however, significant increases were also detected in northern districts of Ukraine and in parts of the Bryansk and Kaluga regions of Russia, where widespread radioactive pollution had been observed (8). To date, nearly 700 extra cases of childhood thyroid cancer have been detected in a population of about 3 million children at risk, and estimates of the future rate of childhood thyroid cancers vary from 0.5 to 3 per 1 million children (3). Published rates of childhood thyroid cancer are shown in Table 1.

A notable factor in the observed increase in thyroid cancer incidence is distance from the accident site. For instance, in Finland, which is about 1,000 km from the release site, no apparent increase in childhood thyroid cancer seems to have occurred by the end of 1993 (3). However, it should be underlined that in Finland all children at risk of radioactive  $^{131}\text{I}$  exposure received iodine treatment, whereas children from radioactivity-contaminated territories in the Ukraine, Belarus and Russia in the former Soviet Union did not have this opportunity at the time.

Evidence as to the frequency of childhood leukemia in areas near Chernobyl has shown no distinct association with radioactive fallout (9). However, the rate of infant leukemia as a result of *in utero* exposure, a distinct form associated with specific genetic abnormality, was increased in Greece 2.6-fold compared to unexposed children, and in Germany, after the Chernobyl accident (10, 11). In Belarus, increased incidence of autoimmune thyroiditis, and endocrine,

**Table I** Rates of childhood thyroid cancer in those territories of Belarus, Ukraine and Russia contaminated in the Chernobyl accident (7)

Area	1981-1985		1986-1990		1991-1994	
	No.	Rate (per million)	No.	Rate (per million)	No.	Rate (per million)
Belarus (all)	3	0.3	47	4	286	30.6
Gomel region	1	0.5	21	10.5	143	96.4
Ukraine - five northern regions	1	0.1	21	?	97	11.5
Russia - Bryansk and Kaluga regions	0	0	3	1.2	20	10

digestive, dermatologic, hematopoietic and mental disorders have been reported (6).

It is worth noting that children's exposure to ionizing radiation is not limited to the environment. Medical radiation exposure occurs during diagnosis, therapy and dental radiography. Epidemiologic studies have shown that people exposed to high levels of ionizing radiation have an increased risk of cancer, particularly leukemia and, later in life, breast and thyroid cancer (12). In addition, some epidemiologic studies have found that radiation exposure during childhood carries a higher risk of cancer than exposure at other ages (12, 13). Thus, the problem of childhood protection from the harmful action of radiation is of widespread significance.

The issue of the treatment of children living in contaminated areas is particularly pressing. Almost all of them suffer from various chronic health disorders, including anemia and a decrease in both specific and nonspecific immunity. Therefore, drugs used in the therapy of these children must have the minimum of side effects and, in the optimal scenario, improve the status of their immune system. In accordance with these requirements, Ukrain attracted our attention as a drug with proven immunomodulating properties (14). Of special significance is the fact that Ukrain has unique radioprotective effects: It protects normal human fibroblasts from radiation toxicity, while enhancing radiation toxicity in colorectal and

brain tumor cells (15). The pronounced radioprotective effect of this drug was also described previously (16).

The absence of serious side effects, and our experience of Ukrain administration in children, prompted us to use this drug in the treatment of recurrent bronchopulmonary pathology in children from areas contaminated after the Chernobyl accident. In all these children, various abnormalities in immune status were found, and so administration of Ukrain as an immunomodulatory drug was directly indicated.

#### Patients and methods

Ukrain (Nowicky Pharma, Vienna, Austria) was clinically administered at three pediatric centers in the Kiev region. The study included 38 children aged 3-14 years with chronic bronchopulmonary diseases, who were from areas contaminated after the Chernobyl accident. The Pharmacological Committee of the Ministry of Health of Ukraine gave permission for clinical studies with Ukrain to be conducted, and the study design was approved by the local ethics committee. Before the treatment was started, a written informed consent had been obtained from parents of all children involved in the study.

Ukrain was administered intravenously at a dose of 5 mg (5 ml) twice a week, up to a total dosage of 35 mg (35 ml). The control group included 10 children with the same diagnosis who were treated with



standard nonspecific anti-inflammatory therapy. A further healthy group consisted of 20 children of the same age without health disorders, who received no treatment.

All children were given a detailed clinical examination before treatment, and those in the two treat-

ment groups were found to have considerable immune status abnormalities.

The influence of Ukrain on hematological (*i.e.*, blood count) and immunological parameters was evaluated. The influence of Ukrain on cellular immunity was monitored by monoclonal antibodies to CD4

**Table II** Blood count parameters of patients treated with Ukrain (Ukrain group), patients treated traditionally (control group), and healthy children (healthy group)

Parameters	Group	On admission	After the course of treatment
RBC ( $10^{12}/l$ )	Healthy	$4.8 \pm 0.2$	-
	Control	$4.7 \pm 0.2$	$4.6 \pm 0.2$
	Ukrain	$4.7 \pm 0.2$	$4.7 \pm 0.2$
Hemoglobin (g/l)	Healthy	$130 \pm 5$	-
	Control	$119 \pm 3$	$126 \pm 7$
	Ukrain	$123 \pm 5$	$122 \pm 5$
Platelets ( $10^9/l$ )	Healthy	$266 \pm 16$	-
	Control	$235 \pm 23$	$240 \pm 26$
	Ukrain	$246 \pm 31$	$252 \pm 21$
WBC ( $10^9/l$ )	Healthy	$5.0 \pm 0.6$	-
	Control	$13.9 \pm 2.7$	$7.3 \pm 3.8^*$
	Ukrain	$14.3 \pm 2.2$	$5.9 \pm 1.5^*$
Eosinophils (%)	Healthy	$1.8 \pm 0.4$	-
	Control	$1.2 \pm 0.6$	$1.4 \pm 1.0$
	Ukrain	$1.3 \pm 0.2$	$1.9 \pm 0.8$
Stabs (%)	Healthy	$1.7 \pm 0.2$	-
	Control	$2.2 \pm 0.6$	$1.9 \pm 0.2$
	Ukrain	$2.0 \pm 0.5$	$2.0 \pm 0.4$
Filamented (%)	Healthy	$56.8 \pm 6.9$	-
	Control	$60.2 \pm 8.1$	$55.6 \pm 4.4$
	Ukrain	$56.9 \pm 9.0$	$59.9 \pm 6.7$
Basophils (%)	Healthy	$0.2 \pm 0.1$	-
	Control	$0.3 \pm 0.2$	$0.2 \pm 0.1$
	Ukrain	$0.2 \pm 0.1$	$0.2 \pm 0.1$
Lymphocytes (%)	Healthy	$34.1 \pm 2.8$	-
	Control	$30.9 \pm 5.4$	$31.2 \pm 6.1$
	Ukrain	$32.7 \pm 6.6$	$33.1 \pm 4.2$
Monocytes (%)	Healthy	$6.7 \pm 2.8$	-
	Control	$7.9 \pm 3.3$	$6.5 \pm 0.2$
	Ukrain	$8.4 \pm 5.5$	$4.4 \pm 1.2$
BSR (mm/h)	Healthy	$6.1 \pm 2.4$	-
	Control	$14.7 \pm 2.9$	$8.3 \pm 2.7^*$
	Ukrain	$15.3 \pm 3.3$	$5.3 \pm 0.9^*$

\* $p < 0.05$  in comparison with control group. RBC = red blood cells, WBC = white blood cells, BSR = blood sedimentation rate.

(helpers) and CD8 (suppressors-killers); the number of T-cells in the peripheral blood was determined by their capacity to form rosettes with three or more sheep erythrocytes. Serum immunoglobulins were measured by the radial immune-diffusion method (Fisher Scientific GmbH, Schwerte, Germany).

Statistical analysis of the data was carried out using Student's *t*-test;  $p < 0.05$  was considered statistically significant.

## Results

Observation of the impact of Ukrain was carried out over a 5-week period. The resulting data were compared with the results of standard treatment in children with a similar pathology in the control group and also with the data for the 20 children without any health disorders.

It was clinically established that after two to three injections of Ukrain, a decrease in the clinical symp-

toms of disease was observable: general debility lessened, sense of well-being improved, and in nine children high body temperatures normalized. In all children in the Ukrain-treated group there was also increased release of bronchial secretion and easier separation, the purulent mucus acquiring a mucilaginous character. After three to four injections of Ukrain, coughing became more productive in character, then gradually decreased, and after five to six injections it disappeared completely. During the course of treatment, the results of percussion and auscultation objective examinations returned to normal in all these children.

Laboratory findings of the blood count parameters and the parameters of the immune status before and after treatment are presented in Tables II, III and IV, respectively.

Compared with the group treated traditionally, the Ukrain group exhibited more pronounced anti-inflammatory activity: this was indicated by greater decreases in both white blood cell count and blood

**Table III** Serological parameters of the immune status of patients treated with Ukrain (Ukrain group), patients treated traditionally (control group) and healthy children (healthy group)

Parameters	Group	On admission	After the course of treatment
IgG (g/l)	Healthy	10.05 ± 1.12	—
	Control	8.42 ± 1.43	8.61 ± 1.07
	Ukrain	7.80 ± 0.56	9.01 ± 1.22*
IgA (g/l)	Healthy	1.91 ± 0.22	—
	Control	1.46 ± 0.17	1.43 ± 0.56
	Ukrain	1.51 ± 0.46	1.57 ± 0.71
IgM (g/l)	Healthy	1.23 ± 0.17	—
	Control	1.10 ± 0.09	1.20 ± 0.14
	Ukrain	0.96 ± 0.11	1.10 ± 0.10
Complement titre (%)	Healthy	58 ± 7	—
	Control	56 ± 9	58 ± 10
	Ukrain	57 ± 11	55 ± 6
Phagocytic activity of neutrophils (%)	Healthy	63 ± 4	—
	Control	52 ± 5	55 ± 2
	Ukrain	52 ± 3	59 ± 1*

\* $p < 0.05$  in comparison with control group. Ig = immunoglobulin

**Table IV** Cellular parameters of the immune status of patients treated with Ukrain (Ukrain group), patients treated traditionally (control group), and healthy children (healthy group)

Parameters	Group	On admission	After the course of treatment
Total lymphocytes (%)	Healthy	34.09 ± 2.06	—
	Control	35.09 ± 1.98	34.99 ± 1.48
	Ukrain	34.75 ± 1.32	37.18 ± 1.23*
T-lymphocytes (%)	Healthy	42.30 ± 1.12	—
	Control	42.27 ± 0.87	42.01 ± 1.01
	Ukrain	42.50 ± 0.24	45.00 ± 0.24*
T-helpers (CD4) (%)	Healthy	57.44 ± 2.01	—
	Control	56.89 ± 2.44	57.05 ± 1.83
	Ukrain	57.03 ± 1.08	62.45 ± 1.12*
T-suppressors (CD8) (%)	Healthy	9.02 ± 0.18	—
	Control	9.79 ± 0.24	9.55 ± 0.37
	Ukrain	9.91 ± 0.31	8.59 ± 0.55
T-helper/T-suppressor ratio	Healthy	6.01 ± 0.09	—
	Control	5.82 ± 0.17	5.97 ± 0.10
	Ukrain	5.76 ± 0.08	7.22 ± 0.13*

\*  $p < 0.05$  in comparison with control group

sedimentation rate. The strong immunomodulatory effect of Ukrain was indicated in the stimulation of specific humoral and cellular immunity: increases in the immunoglobulin G (IgG) level; the phagocytic activity of neutrophils; the number of total lymphocytes, T-lymphocytes and T-helpers; and the T-helper/suppressor ratio.

## Discussion

The differences in the results of therapy between the two treatment groups (with and without Ukrain) are remarkable. In the Ukrain group, the improvement of immune status, decrease in inflammation and improvement in clinical situation were really surprising, especially in comparison with the results from the group treated traditionally.

The study was performed in children with deep and long-lasting changes in immune status provoked

by external ionizing radiation. Diseases and health abnormalities in this group of young patients are hard to prevent and hard to cure. Thus, the observed results are of great significance.

In the 15 years after the Chernobyl accident, there was an increase in the incidence of endocrinal and dermatological disorders, disorders of the digestive organs, chronic tonsillitis and adenoiditis, and autoimmune thyroiditis (6).

We suggest that this entire complex of health disorders in children, being the most sensitive section of the human population, can be labelled Chernobyl syndrome: a decrease in the immune resistance of the organism to infection and cancer as a result of the effects of exposure to radiation from Chernobyl. In view of the results of this pilot study and the importance of preventive and clinical investigation of this problem given the widespread use of nuclear power stations and the risk of radiation from military sources, further studies devoted to the effect of Ukrain on chil-

dren with immune disorders from radiation-contaminated areas would be of great significance and great potential benefit.

### Acknowledgments

This study was performed thanks to the support of Dr. Oleh Tyahnybok from Kiev, Ukraine, a member of the Ukrainian Parliament, and of Dr. Wassil Nowicky from Vienna, Austria.

### References

- (1) Fry R.J. *Deterministic effects*. *Health Phys.*, **60**(4), 338, 2001.
- (2) *1990 Recommendations of the International Commission on Radiological Protection*. *Ann. ICRP*, **21**, 1, 1991.
- (3) Rytomaa T. *Ten years after Chernobyl*. *Ann. Med.*, **28**(2), 83, 1996.
- (4) Lindholm C., Salomaa S., Tekkel M., et al. *Biodosimetry after accidental radiation exposure by conventional chromosome analysis and FISH*. *Int. J. Radiat. Biol.*, **70**(6), 647, 1996.
- (5) Likhtarev I.A., Sobolev B.G., Karo I.A., et al. *Thyroid cancer in Ukraine*. *Nature*, **375**(6530), 365, 1995.
- (6) Lomat L., Galbut G., Quastel M.R., Polyakov S., Okeanov A., Rozin S. *Incidence of childhood disease in Belarus associated with the Chernobyl accident*. *Environ. Health Perspect.*, **105** (Suppl. 6), 1529, 1997.
- (7) Staszko VA, Tsyb A.F., Ironko N.D., Souchkevitch G., Baverstock K.F. *Childhood thyroid cancer since the accident at Chernobyl*. *Br. Med. J.*, **310**(6982), 801, 1995.
- (8) Parkin D.M., Cardis E., Masuyer L., et al. *Childhood leukaemia following the Chernobyl accident: the European Childhood Leukaemia-Lymphoma Incidence Study (ECLIS)*. *Eur. J. Cancer*, **29A**(1), 87, 1992.
- (9) Kuchuk A.A. *Health problems of the population in different regions of the Ukraine*. *Toxicol. Lett.*, **72**(1-3), 213, 1994.
- (10) Sak D., Cardis E., Szlanyik L., et al. *Cancer consequences of the Chernobyl accident in Europe outside the former USSR: A review*. *Int. J. Cancer*, **67**(3), 343, 1996.
- (11) Steiner M., Barkart W., Grosche B., Kaletsch U., Michaels J. *Trends in infant leukaemia in West Germany in relation to in utero exposure due to the Chernobyl accident*. *Radiat. Environ. Biophys.*, **37**(2), 87, 1996.
- (12) Miller R.W. *Delayed effects of external radiation exposure: A brief history*. *Radiat. Res.*, **144**(2), 160, 1995.
- (13) Yoshimoto Y., DeLongchamp R., Mabuchi K. *In-utero exposed atomic bomb survivors: Cancer risk update*. *Lancet*, **344**(8918), 345, 1994.
- (14) Uglyantsa K.N., Nelyodov L.I., Doroshenko Y.M., et al. *Ukrain: A novel antitumor drug*. *Drugs Exptl. Clin. Res.*, **26**(5/6), 341, 2000.
- (15) Cordes N., Plasswilm L., Bamberg M., Rodemann H.P. *Ukrain®: an alkaloid thophosphonic acid derivative of *Chelidonium majus* L. protects human fibroblasts but not human tumour cells in vitro against ionizing radiation*. *Int. J. Radiat. Biol.*, **78**(1), 17, 2002.
- (16) Boyko W.N., Zhelus R.B. *A comparative evaluation of the influence of the complex drug Ukrain and its components on the effects of radiation*. *Drugs Exptl. Clin. Res.*, **24**(5/6), 13, 1998.

Research article

Open Access

## Ukrain – a new cancer cure? A systematic review of randomised clinical trials

E Ernst\* and K Schmidt

Address: Complementary Medicine, Peninsula Medical School, Universities of Exeter & Plymouth, 25 Victoria Park Road, Exeter EX2 4NT

Email: E Ernst\* - edzard.ernst@pms.ac.uk; K Schmidt - katja.schmidt@pms.ac.uk

\* Corresponding author

Published: 01 July 2005

Received: 17 March 2005

BMC Cancer 2005, 5:69 doi:10.1186/1471-2407-5-69

Accepted: 01 July 2005

This article is available from: <http://www.biomedcentral.com/1471-2407/5/69>

© 2005 Ernst and Schmidt; licensee BioMed Central Ltd.

This is an Open Access article distributed under the terms of the Creative Commons Attribution License (<http://creativecommons.org/licenses/by/2.0>), which permits unrestricted use, distribution, and reproduction in any medium, provided the original work is properly cited.

### Abstract

**Background:** Ukrain is an anticancer drug based on the extract of the plant *Chelidonium majus* L. Numerous pre-clinical and clinical investigations seem to suggest that Ukrain is pharmacologically active and clinically effective. We wanted therefore to critically evaluate the clinical trial data in the form of a systematic review.

**Methods:** Seven electronic databases were searched for all relevant randomised clinical trials. Data were extracted and validated by both authors, tabulated and summarised narratively. The methodological quality was assessed with the Jadad score.

**Results:** Seven trials met our inclusion criteria. Without exception, their findings suggest that Ukrain has curative effects on a range of cancers. However, the methodological quality of most studies was poor. In addition, the interpretation of several trials was impeded by other problems.

**Conclusion:** The data from randomised clinical trials suggest Ukrain to have potential as an anticancer drug. However, numerous caveats prevent a positive conclusion, and independent rigorous studies are urgently needed.

### Background

Ukrain (NSC-631570) is a semi-synthetic compound derived from the common weed, greater celandine (*Chelidonium majus* L.). This plant contains a range of alkaloids, most notably chelidoniumine, also known as benzophenanthridine alkaloid. A leaflet distributed to patients at the Bristol Cancer Help Centre, United Kingdom, describes Ukrain as "the only known product, which at present does not also destroy healthy cells, and which reduces tumors and boosts the immune system..." [1]. Ukrain is most commonly administered intravenously and consists of one molecule thiophosphoric acid conjugated to three molecules of chelidoniumine. It has drug licenses in several states of the former Soviet Union.

Research on Ukrain started about 20 years ago. Meanwhile, numerous in-vitro studies [2-37] animal experiments [38-83], case reports [84-97], and case series [98-108] have emerged. Collectively, these data suggest that Ukrain has anticancer activity in a wide range of cell lines, which could be of clinical value. Whether or not this translates into clinical effectiveness and whether or not Ukrain does indeed cure some type of cancer or improves their prognosis can best be decided on the basis of randomised clinical trials (RCTs). This systematic review is aimed at summarising and critically evaluating all such studies.

## Methods

Electronic literature searches were conducted in the following databases: MEDLINE (1966 to date, via Pubmed), EMBASE (1974 to date), CINAHL (Cumulative Index to Nursing and Allied Health Literature, 1982 to date), AMED (Allied and Complementary Medicine Database, 1985 to date), PsycINFO (1987 to date), DIMDI (Deutsches Institut für Medizinische Dokumentation und Information) and The Cochrane Central Register of Controlled Trials (CENTRAL). The following search terms were used: 'Ukrain', 'chelidonium', 'greater celandine', 'cancer', 'neoplasm' or 'tumour'. Further handsearches were performed in our unit's own files as well as in the reference lists of all located articles. The producer of Ukrain was also contacted. No restrictions regarding the language of publication were imposed.

We included all RCTs of Ukrain as a treatment for any type of human cancer. Ukrain could be used as a sole treatment or as an adjunct to conventional therapy. Any type of intervention was permitted in the control groups. The clinical endpoints had to be survival or parameters indicative of tumour burden. Non-randomised studies or RCTs that did not quantify clinical endpoints were excluded [e.g. [109-117]], as were duplicates [118].

All articles were read in full by both authors and data relating to design, diagnosis, number of subjects, treatments for experimental and control groups, outcome measures and results were extracted independently by both authors. The methodological quality of each trial was assessed using the Jadad score, unless the study was only available in abstract form [119]. It evaluates methodological quality using three items assessing random allocation, double-blinding and the reports of withdrawals and drop-outs and a maximum of 5 points can be given if all criteria are met. The authors agreed to a consensus on the assessed data and cases of discrepancy would be settled by discussion. Because of overt clinical heterogeneity, a meta-analysis was deemed unreasonable. Descriptive summaries of the data are presented in the following text.

## Results

Our search strategy identified 7 RCTs [120-126]. The majority of these studies was published in two different journals between 1995 and 2002 by 4 different groups of authors from the Belarus and Germany. Key data from these studies are summarised in Table 1 and will be discussed below.

Susak et al published an RCT in which 108 colorectal cancer patients received either Ukrain as a monotherapy or 5-fluorouracil for an unspecified time duration [126]. The results suggest that this was followed by non-progression of the malignancy in 88.8% of the patients in the experi-

mental group compared to 27.7% in the control group. This study is only reported in abstract form. Numerous methodological details are therefore not accessible and its methodological quality cannot be reliably assessed.

One year later, the same research group published a similar clinical trial, this time including 96 colorectal cancer patients [120]. Forty-eight patients received Ukrain as a monotherapy and 48 patients received 5-fluorouracil and radiation. The survival rate differed substantially between the two groups. Two-year survival was 78.6% in the experimental group compared to 33.3% in the control group. This study was not blinded but applied an appropriate method of randomisation.

Bondar et al treated 48 histologically verified rectal cancer patients either with X-ray radiotherapy, chemotherapy and surgery (control group) or with Ukrain and surgery (experimental group) [121]. Before and after these treatments, the authors measured 19 different laboratory parameters including two tumour markers. In addition, the Karnofsky Index, tumour dimensions, and recurrences were monitored. All of these variables strongly favoured Ukrain therapy over conventional treatment. This study has, however, numerous limitations. For instance, the method of randomisation was not explained; the authors merely stated that "all patients were subdivided into two randomised groups". Moreover, "tumour dimensions" were mentioned as an outcome measure but neither the methodology of measurement nor the results were provided. The recurrence rates are expressed as percentage figures and no test statistics seem to have been applied.

Uglyanitsa et al conducted a study with 28 patients suffering from bladder cancer [116] aiming "to evaluate the efficacy of Ukrain". Patients were allocated to three groups treated with a total dose of 100 (group 1), 200 (group 2), or 300 mg Ukrain (group 3). Two weeks later tumour regression was verified through cystoscopy and ultrasound. Complete and partial regression was noted in 0/4 patients of group 1, 1/4 patients of group 2, and 2/6 patients of group 3. This study lacks many characteristics of a rigorous trial; its stated aims (to evaluate efficacy) cannot be achieved with the study design, which essentially was that of an equivalence or dose-finding study.

Zemskov and colleagues published a "pilot study" with 42 patients suffering from pancreas cancer who had refused chemotherapy [122]. They were randomised to receive either Vitamin C alone or with Ukrain (total dose 100 mg/patient). The primary endpoint (survival) strongly favoured the Ukrain group. The analysis seems to include 4 protocol violations (the description is unclear). Even though the randomisation procedure is mentioned ('closed envelopes') it seems unusual that precisely 21

patients ended up in both groups. The results are surprisingly good – much better than with any other treatment for that condition.

Uglyanitsa et al randomised ("by lottery") 75 breast cancer patients into three groups of 25 patients each [123]. They received either no specific treatment, a total dose of 50 or 100 mg Ukrain 5–7 days before mastectomy. The authors note that Ukrain rendered the primary tumour and the affected regional lymph nodes larger, harder and "more clearly defined". They interpret this as Ukrain-induced tumour sclerosis. According to the investigators' judgement, these changes facilitated surgery and the operative success. In addition, Ukrain was associated with remarkable symptomatic improvements, e.g. better appetite, more sleep, less weakness. The report is unclear in several respects. For instance, no details about statistical analyses are provided, the outcome measures seem subjective, no information regarding investigator blinding is given, and the randomisation procedure seems suspect.

Zemskov and colleagues randomised 42 patients with pancreatic cancer who had refused conventional therapy [124]. They received either Ukrain (total dose 100 mg/patient) with Vitamin C or Vitamin C alone. The results confirmed this group's earlier findings [122]. Survival was remarkable in the Ukrain treated patients and symptoms responded well to this treatment. There are, however, numerous puzzling details. Why do the authors call their second study a "pilot study"? Why did their ethics committee consent to this "placebo"-controlled trial in the knowledge of the surprisingly positive earlier results? How could a proper randomisation again result in two equally sized groups of 21? In the discussion, the authors describe their earlier results as though this trial was conducted against 5-FU which, in fact, is not the case [122].

Gansauge et al reported a study of 90 patients with pancreatic cancer treated either with 1000 mg gemcitabine/m<sup>2</sup> or 100 mg Ukrain or the combination of both regimens [125]. Survival rates suggested that Ukrain was superior to gemcitabine alone. A direct comparison of the 12 month survival rates revealed large differences compared to the data from Zemskov et al [124] (29% vs 76% in the Ukrain-treated groups). The randomisation procedure was not explained and, again, the equal group sizes are remarkable.

### Conclusion

Collectively, these RCTs seem to suggest that Ukrain is an effective therapy for a range of cancers. In conjunction with the numerous encouraging case reports [84-97] case series [98-108], and non-randomised clinical trials [109-121] these data look impressive at first glance. Yet several important caveats need to be considered.

None of the RCTs in this systematic review is without serious methodological limitations. The Jadad score [119] of most RCTs was low. Their sample size was usually small, and a sample size calculation to define the number of patients required was lacking in most cases. Even though most RCTs were non-inferiority studies by design and purpose, their statistical approach was that of a superiority trial. The majority of RCTs were conducted in Ukrainian research institutes and published in only two different journals. In several trials, there are clear signs of involvement of the manufacturer of Ukrain. Most RCTs have generally been poorly evaluated and reported, which possibly reflects the poverty of clinical science in Eastern Europe. Independent replications are not available. The only German study [125] has also been heavily criticised: its sample size (30 patients in each group) is minute, the report lacks statistical detail and there is an inequality of treatment cycles between groups [127]. It was also noted that this study (the only RCT not published in the same two journals as all the other RCTs) was published in a journal for which the senior author served as editor [127]. No RCTs were found showing negative or near neutral results; this might suggest the existence of publication bias for which we did, however, find no definite proof.

Greater celandine (*Chelidonium majus* L.), which forms the basis of Ukrain, was traditionally used for liver and gall-bladder complaints, loss of appetite and gastroenteritis. None of these indications is supported by trial evidence. The main alkaloid from this plant, chelidonine, has antispasmodic, weak central analgesic and papaverine-like effects. In animal experiments, an alcoholic extract of greater celandine increased bile flow, caused non-specific immune stimulation and acted as a hepatoprotectant [128]. The oral administration of greater celandine in humans has been associated with several cases of toxic hepatitis [129].

The mechanism of action of Ukrain as an anticancer drug (if any) remains elusive. Collectively, the preclinical studies are suggestive of antineoplastic and immunomodulatory effects. It has been postulated that the antineoplastic effect is due to the alkaloids interfering with the metabolism of cancer cells, diminished synthesis of DNA, RNA and proteins, the inhibition of cellular oxygen consumption, and the induction of programmed cell death in malignant cells [130].

Several reports of adverse reactions after greater celandine have been published. Most notably, toxic hepatitis has been associated with its oral use [129,131,132]. No case reports of adverse events have emerged of intravenous Ukrain therapy for cancer. The clinical trial data suggest that Ukrain might cause the following adverse effects: an increase in patients' body temperature (n = 26)

[120,123,125], general burning sensations (n = 3) [123] and bleeding (n = 4) [125]. Levels between 0-2 according to World Health Organisation toxicity criteria were noted in two trials [122,124] and toxicity criteria between 0-3 were observed in one trial [125]. The costs of Ukrain therapy are high; one course costs € 700 for the medication alone, and the total treatment costs have been estimated at € 3000 per week [133].

In conclusion, Ukrain is a plant-based anticancer drug that is supported by clinical and pre-clinical evidence in a range of malignancies. The data are, however, not free from problems. Before positive recommendations can be issued, independent replications with definite trials and larger sample sizes seem mandatory.

### Competing interests

The author(s) have no competing interests to declare.

### Authors' contributions

EE conceived of the review, participated in its design and coordination, the data extraction and helped to draft the manuscript. KS carried out the data extraction and helped drafting the manuscript. All authors read and approved the final manuscript.

### References

- Miller S: **Ukrain**. Bristol Cancer Help Centre 'handout' dated 05/03/2004 2004. (unpublished)
- Nowicky J, Greif M, Hamler F, Hiesmayr W, Staub W: **Biological activity of ukrain in vitro and in vivo**. *Chemioterapia* 1987, 6:683-5.
- Hohenwarter O, Strutzenberger K, Katinger H, Liepins A, Nowicky JW: **Selective inhibition of in vitro cell growth by the anti-tumour drug Ukrain**. *Drugs Exp Clin Res* 1992, 18:1-4.
- Bruller W: **Studies concerning the effect of Ukrain in vivo and in vitro**. *Drugs Exp Clin Res* 1992, 18:13-6.
- Slesak B, Nowicky JW, Harlozinska A: **In vitro effects of Chelidonium majus L. alkaloid thiophosphoric acid conjugates (Ukrain) on the phenotype of normal human lymphocytes**. *Drugs Exp Clin Res* 1992, 18:17-21.
- Chlopkiewicz B, Marczevska J, Ejchart A, Anuszewska E, Kozirowska J: **Evaluation of mutagenic, genotoxic and transforming properties of Ukrain**. *Drugs Exp Clin Res* 1992, 18:31-4.
- Sotomayor EM, Rao K, Lopez DM, Liepins A: **Enhancement of macrophage tumoricidal activity by the alkaloid derivative Ukrain. In vitro and in vivo studies**. *Drugs Exp Clin Res* 1992, 18:5-11.
- Staniszewski A, Slesak B, Kolodziej J, Harlozinska-Szymrka A, Nowicky JW: **Lymphocyte subsets in patients with lung cancer treated with thiophosphoric acid alkaloid derivatives from Chelidonium majus L. (Ukrain)**. *Drugs Exp Clin Res* 1992, 18:63-7.
- Kleinrok Z, Jagiello-Wojtowicz E, Matuszek B, Chodkowska A: **Basic central pharmacological properties of thiophosphoric acid alkaloid derivatives from Chelidonium majus L.** *Pol J Pharmacol Pharm* 1992, 44:227-39.
- Thakur ML, DeFulvio J, Tong J, John E, McDevitt MR, Damjanov I: **Evaluation of biological response modifiers in the enhancement of tumor uptake of technetium-99 m labeled macromolecules. A preliminary report**. *J Immunol Methods* 1992, 152:209-16.
- Liepins A, Nowicky JW: **Activation of spleen cell lytic activity by the alkaloid thiophosphoric acid derivative: Ukrain**. *Int J Immunopharmacol* 1992, 14:1437-42.
- Jodlowska-Jedrych B: **Morphological studies on rat's liver after a ten-day treatment with Chelidonium majus L. alkaloid thiophosphoric acid derivative (Ukrain)**. *Ann Univ Mariae Curie Sklodowska [Med]* 1994, 49:119-24.
- Liepins A, Nowicky JW, Bustamente JO, Lam E: **Induction of bimodal programmed cell death in malignant cells by the derivative Ukrain (NSC-631570)**. *Drugs Exp Clin Res* 1996, 22:73-9.
- Nowicky JW, Hiesmayr W, Nowicky W, Liepins A: **Influence of Ukrain on DNA, RNA and protein synthesis in malignant cells**. *Drugs Exp Clin Res* 1996, 22:81-91.
- Nowicky JW, Hiesmayr W, Nowicky W, Liepins A: **Influence of Ukrain on human xenografts in vitro**. *Drugs Exp Clin Res* 1996, 22:93-7.
- Jin JM, Nowicky JW, Liepins A: **Mitogenic properties of Ukrain (NSC-6315170) on human peripheral blood monocytes: clinical implications**. *Drugs Exp Clin Res* 1996, 22:99-101.
- Liepins A, Nowicky JW: **Modulation of immune effector cell cytolytic activity and tumour growth inhibition in vivo by Ukrain (NSC 631570)**. *Drugs Exp Clin Res* 1996, 22:103-13.
- Susak YM, Kurik MV, Kravchenko OV, Zemskov SV: **Certain biophysical properties of Ukrain**. *Drugs Exp Clin Res* 1996, 22:185-7.
- Zhalilo LI, Susak YM, Zemskov SV, Susak IA: **Influence of Ukrain on the redox processes of hepatocytes**. *Drugs Exp Clin Res* 1996, 22:189-91.
- Brzosko WJ, Graczyk A, Konarski J, Nowicky JW: **Synergic influence of Ukrain and photoporphyrin amino acid conjugates on human malignant cell lines**. *Drugs Exp Clin Res* 1996, 22:193-4.
- Ciebiada I, Korczak E, Nowicky JW, Denys A: **Estimation of direct influence of Ukrain preparation on influenza viruses and the bacteria E. coli and S. aureus**. *Drugs Exp Clin Res* 1996, 22:219-23.
- Voltchek I, Kamyshentsev M, Lavinsky Y, Nowicky J, Medvedev Y, Litvinchuk L: **Comparative study of the cytostatic effects of Oliphen and Ukrain**. *J Chemother* 1996, 8:144-6.
- Korolenko TA, Kaledin VI, Svechnikova IG, Li XV, Stashko JF, Ilnit-skaya SI, et al.: **Study of the antitumour effect of Ukrain: the role of macrophage secretion of alpha-1-proteinase inhibitor**. *Drugs Exp Clin Res* 1998, 24:271-6.
- Kulik GI: **Comparative in vitro study of the effects of the new antitumour drug Ukrain and several cytostatic agents on the thiol groups in the tissue of Guerin carcinoma and its resistance to cisplatin variant**. *Drugs Exp Clin Res* 1998, 24:277-80.
- Boyko VN, Belskiy SN: **The influence of the novel drug Ukrain on hemo- and immunopoiesis at the time of its maximum radioprotective effect**. *Drugs Exp Clin Res* 1998, 24:335-7.
- Panzer A, Hamel E, Joubert AM, Bianchi PC, Seegers JC: **Ukrain™, a semisynthetic Chelidonium majus alkaloid derivative, acts by inhibition of tubulin polymerization in normal and malignant cell lines**. *Cancer Lett* 2000, 160:149-57.
- Panzer A, Joubert AM, Eloff JN, Albrecht CF, Erasmus E, Seegers JC: **Chemical analyses of Ukrain, a semi-synthetic Chelidonium majus alkaloid derivative, fail to confirm its trimeric structure**. *Cancer Lett* 2000, 160:237-41.
- Roublevskaia IN, Polevoda BV, Ludlow JW, Haake AR: **Induced G2/M arrest and apoptosis in human epidermoid carcinoma cell lines by semisynthetic drug Ukrain**. *Anticancer Res* 2000, 20:3163-7.
- Panzer A, Joubert AM, Bianchi PC, Seegers JC: **The antimetabolic effects of Ukrain, a Chelidonium majus alkaloid derivative, are reversible in vitro**. *Cancer Lett* 2000, 150:85-92.
- Panzer A, Joubert AM, Bianchi PC, Hamel E, Seegers JC: **The effects of chelidonine on tubulin polymerisation, cell cycle progression and selected signal transmission pathways**. *Eur J Cell Biol* 2001, 80:111-8.
- Roublevskaia IN, Haake AR, Ludlow JW, Polevoda BV: **Induced apoptosis in human prostate cancer cell line LNCaP by Ukrain**. *Drugs Exp Clin Res* 2000, 26:141-7.
- Roublevskaia IN, Haake AR, Polevoda BV: **Bcl-2 overexpression protects human keratinocyte cells from Ukrain-induced apoptosis but not from G2/M arrest**. *Drugs Exp Clin Res* 2000, 26:149-56.
- Voltchek I, Sologub T, Nowicky JW, Grigoryeva T, Belozorova L, Belopolskaya M, et al.: **Preliminary results of individual therapy of chronic hepatitis C by Ukrain and interferon-alpha**. *Drugs Exp Clin Res* 2000, 26:261-6.



34. Votrin II, Voltchek IV, Kurochkin SN, Kolobkov SL: **Effects of Ukrain on the activities of DNA-nicking enzymes.** *Drugs Exp Clin Res* 2000, **26**:267-73.
35. Jagiello-Wojtowicz E, Dudka J, Dawidek-Pietryka K: **Effect of Ukrain on human liver alcohol dehydrogenase activity in vitro.** *Drugs Exp Clin Res* 2000, **26**:337-9.
36. Kuznetsova LP, Nikol'skaia EB, Sochilina EE, Faddeeva MD: **The inhibition enzymatic hydrolysis of acetylthiocholine by acetylcholinesterase using principle alkaloids isolated from celandine and macleya and their derivatives.** *Tsitologija* 2001, **43**:1046-50.
37. Cordes N, Bläse MA, Plasswilm L, Rodemann HP, Van Beuningen D: **Fibronectin and laminin increase resistance to ionizing radiation and the cytotoxic drug Ukrain in human tumour and normal cells in vitro.** *Int J Radiat Biol* 2003, **79**:709-20.
38. Kleinrok Z, Jagiello-Wojtowicz E, Nowicky JW, Chodkowska A, Feldo M, Matuszek B: **Some pharmacological properties of prolonged administration of Ukrain in rodents.** *Drugs Exp Clin Res* 1992, **18**:93-6.
39. Jagiello-Wojtowicz E, Kleinrok Z, Chodkowska A, Feldo M, Nowicky JW: **Modification of antinociceptive action of morphine by Ukrain in rodents.** *Drugs Exp Clin Res* 1992, **18**:101-5.
40. Jagiello-Wojtowicz E, Kleinrok Z, Feldo M, Chodkowska A, Nowicky JW: **Effect of Ukrain on the efficacy of anti-epileptic drugs against maximal electroshock-induced seizures in mice.** *Drugs Exp Clin Res* 1992, **18**:107-9.
41. Juszkiewicz T, Minta M, Włodarczyk B, Biernacki B: **Teratological evaluation of Ukrain in hamsters and rats.** *Drugs Exp Clin Res* 1992, **18**:23-9.
42. Wyczolkowska J, Czuwaj M, Maslinski C: **The immunomodulating preparation Ukrain does not induce anaphylactic sensitization in mice and guinea pigs.** *Drugs Exp Clin Res* 1992, **18**:35-8.
43. Jagiello-Wojtowicz E, Kleinrok Z, Matuszek B, Surmaczynska B, Baran E, Nowicky JW, et al.: **Effect of three months treatment with Ukrain on peripheral blood morphology in rodents.** *Drugs Exp Clin Res* 1992, **18**:79-83.
44. Jagiello-Wojtowicz E, Kleinrok Z, Surmaczynska B, Baran E, Feldo M, Nowicky JW: **Effect of single and three months treatment with Ukrain on aminotransferases (ALT and AST) and on the serum protein level in rodents.** *Drugs Exp Clin Res* 1992, **18**:85-7.
45. Jagiello-Wojtowicz E, Kleinrok Z, Nowicky JW, Matuszek B, Baran E, Surmaczynska B: **Effect of single and prolonged administration of Ukrain on prolactin concentration in rats.** *Drugs Exp Clin Res* 1992, **18**:89-91.
46. Matyszek M, Krolkowska-Prasala I, Jedrych B: **Histological appreciation of the stomach after the application of thiophosphoric acid derivatives of Chelidonium majus L. (Ukrain) alkaloids.** *Ann Univ Mariae Curie Sklodowska* 1992, **47**:123-6.
47. Ciebada I, Korczak E, Denys A, Nowicky JW: **Effect of Ukrain preparation on immune response in mice affected by influenza virus.** *J Chemother* 1995, **7**:101-4.
48. Boyko VN, Voltchek IV, Petrov AS, Bubneov VP: **Action of Ukrain, a cytostatic and immunomodulating drug, on effects of irradiation.** *Drugs Exp Clin Res* 1996, **22**:167-71.
49. Jagiello-Wojtowicz E, Kleinrok Z, Nowicky JW, Jablonski M, Gorzelak M, Chodkowska A, et al.: **Effect of six-month treatment with Ukrain on early osteoporosis induced by ovariectomy in rats. Part I: Preliminary studies of bone parameters.** *Drugs Exp Clin Res* 1996, **22**:173-6.
50. Jagiello-Wojtowicz E, Kleinrok Z, Nowicky JW, Chodkowska A, Feldo M, Surmaczynska B, et al.: **Effect of six-month treatment with Ukrain on early osteoporosis induced by ovariectomy in rats. Part II: Preliminary studies of peripheral blood parameters.** *Drugs Exp Clin Res* 1996, **22**:177-80.
51. Jagiello-Wojtowicz E, Kleinrok Z, Nowicky JW, Baran E: **Effect of six-month treatment with Ukrain on early osteoporosis induced by ovariectomy in rats. Part III: Preliminary studies of some hormone levels.** *Drugs Exp Clin Res* 1996, **22**:181-4.
52. Wyczolkowska J, Michon T, Nowicky JW: **Inhibitory effect of thiophosphoric acid alkaloid derivatives from Chelidonium majus L. (Ukrain) on ovalbumin antigenicity and antiovalbumin IgE antibody response in mice.** *Drugs Exp Clin Res* 1996, **22**:195-200.
53. Jagiello-Wojtowicz E, Kleinrok Z, Chodkowska A, Nowicky JW, Piper H, Kubiatowski T: **Antinociceptive effect of ten day administration of Ukrain in mice and interaction of the treatment with morphine.** *Drugs Exp Clin Res* 1996, **22**:201-3.
54. Jagiello-Wojtowicz E, Kleinrok Z, Nowicky JW, Chodkowska A, Kubiatowski T, Piper H: **Interaction between Ukrain and morphine in their ten-day treatment in mice in the writhing syndrome test.** *Drugs Exp Clin Res* 1996, **22**:205-6.
55. Ciebada I, Korczak E, Nowicky JW, Denys A: **Does the Ukrain preparation protect mice against lethal doses of bacteria?** *Drugs Exp Clin Res* 1996, **22**:207-11.
56. Lozjuk RM, Lisnyak OI, Lozjuk LV: **Theoretical grounds and experimental confirmation of the antiviral effect of the preparation Ukrain.** *Drugs Exp Clin Res* 1996, **22**:213-7.
57. Lisnyak OI, Lozjuk RM: **Biological activity of some thiophosphoric derivatives of alkaloids with respect to influenza virus.** *Drugs Exp Clin Res* 1996, **22**:225-8.
58. Todor IN, Kazmin SD, Susak YaM, Zemskov SV: **The influence of glucose, succinate, pH of the medium and higher temperature on the cytotoxic activity of the preparation Ukrain.** *Drugs Exp Clin Res* 1998, **24**:247-52.
59. Korolenko TA, Svechnikova IG, Filjushina EE, Kaledin VI, Vakulin GM, Usynin IF, et al.: **Macrophage stimulation and antitumour effect of Ukrain.** *Drugs Exp Clin Res* 1998, **24**:253-60.
60. Svechnikova IG, Korolenko TA, Stashko JuF, Kaledin VI, Nikolin VP, Nowicky JW: **The influence of Ukrain on the growth of HA-1 tumour in mice: the role of cysteine proteinases as markers of tumor malignancy.** *Drugs Exp Clin Res* 1998, **24**:261-9.
61. Deneka ER: **Morphometric and kinetic analysis of the growth of experimental sarcoma-45 in the presence of Ukrain.** *Drugs Exp Clin Res* 1998, **24**:281-5.
62. Kulik GI, Deneka ER, Todor IN, Karminozina LG: **Study of acute toxicity of Ukrain in rats after intravenous injection.** *Drugs Exp Clin Res* 1998, **24**:287-93.
63. Jagiello-Wojtowicz E, Kleinrok Z, Feldo M, Chodkowska A, Szponar J, Urbanska EM: **Six-week treatment with Ukrain in rabbits. Part I: Morphological parameters.** *Drugs Exp Clin Res* 1998, **24**:295-9.
64. Jagiello-Wojtowicz E, Kleinrok Z, Feldo M, Chodkowska A, Szklarczyk V, Urbanska EM: **Six-week treatment with Ukrain in rabbits. Part II: Serum levels of gonadal hormones.** *Drugs Exp Clin Res* 1998, **24**:301-4.
65. Jagiello-Wojtowicz E, Kleinrok Z, Feldo M, Chodkowska A, Szklarczyk V, Urbanska EM: **Six-week treatment with Ukrain in rabbits. Part III: Serum levels of thyroid hormones.** *Drugs Exp Clin Res* 1998, **24**:305-8.
66. Jagiello-Wojtowicz E, Kleinrok Z, Chodkowska A, Misztal G, Jagiello G: **Preliminary pharmacokinetic studies of Ukrain in rats.** *Drugs Exp Clin Res* 1998, **24**:309-11.
67. Gorzelak M, Jablonski M, Patyra M, Jagiello-Wojtowicz E: **Effect of intermittent three-month treatment with different doses of Ukrain on subregional femoral bone mineral density of sexually mature female rats.** *Drugs Exp Clin Res* 1998, **24**:313-6.
68. Jablonski M, Gorzelak M, Patyra M, Jagiello-Wojtowicz E: **Effect of intermittent three-month treatment with different doses of Ukrain on subregional bone mineral density of the femur of ovariectomized rats.** *Drugs Exp Clin Res* 1998, **24**:317-20.
69. Jagiello-Wojtowicz E, Kleinrok Z, Chodkowska A, Szkodziak A, Siembida E, Gustaw K, et al.: **Modification of antinociceptive action of Ukrain by endogenous nitric oxide in the writhing syndrome test in mice.** *Drugs Exp Clin Res* 1998, **24**:321-5.
70. Jagiello-Wojtowicz E, Kleinrok Z, Gustaw K: **Interaction between Ukrain and Naltrexone in the writhing syndrome test in mice.** *Drugs Exp Clin Res* 1998, **24**:327-30.
71. Boyko VN, Zholus RB: **A comparative evaluation of the influence of the complex drug Ukrain and its components on the effects of radiation.** *Drugs Exp Clin Res* 1998, **24**:331-3.
72. Boyko VN, Levshina YeV: **A study of the influence of a novel drug Ukrain in vivo effects of low-dose ionizing radiation.** *Drugs Exp Clin Res* 1998, **24**:339-41.
73. Boyko VN, Zholus RB, Legeza VI: **A study of the influence of different types of radioprotectors on the survival of mice treated with ionizing radiation over a wide dose range.** *Drugs Exp Clin Res* 1998, **24**:343-7.
74. Hruby R: **Ukrain: acute toxicity after intravenous, intramuscular and oral administration in rats.** *Drugs Exp Clin Res* 2000, **26**:157-61.

75. Doroshenko YM, Karavay AV, Hodysch YY, Uglyanitsa KN, Nowicky JW, Nefyodov LI: **The dynamics of concentration of the main fluorescent component of Ukrain in the tissues and blood plasma of rats with W-256 tumor after a single intravenous injection.** *Drugs Exp Clin Res* 2000, **26**:171-7.
76. Kurochkin SN, Kolobkov SL, Votrin II, Voltchek IV: **Induction of apoptosis in cultured Chinese hamster ovary cells by Ukrain and its synergistic action with etoposide.** *Drugs Exp Clin Res* 2000, **26**:275-8.
77. Korolenko TA, Djanayeva SJ, Falameyeva OV, Wevers RA, Filjushina EE, Buzueva II, et al.: **Chitotriosidase as a new marker of macrophage stimulation in a tumor model treated with cyclophosphamide and Ukrain.** *Drugs Exp Clin Res* 2000, **26**:279-83.
78. Korolenko TA, Poteryaeva ON, Djanayeva SJ, Svechnikova IG, Kaleidn VI, Timofeyeva OA, et al.: **Cystatin C in LS lymphosarcoma and HA-I hepatoma treated with Ukrain and cyclophosphamide and involvement of apoptosis.** *Drugs Exp Clin Res* 2000, **26**:285-92.
79. Djanayeva SJ, Korolenko TA, Svechnikova IG, Falameyeva OV, Korolenko E, Kaledin VI, et al.: **Influence of Ukrain and cyclophosphamide administration on HA-I murine hepatoma and LS lymphoma on aspartic proteinase cathepsin D.** *Drugs Exp Clin Res* 2000, **26**:293-9.
80. Poteryaeva ON, Falameyeva OV, Korolenko TA, Kaledin VI, Djanayeva SJ, Nowicky JW, et al.: **Cysteine proteinase inhibitor level in tumor and normal tissues in control and cured mice.** *Drugs Exp Clin Res* 2000, **26**:301-6.
81. Luksa-Lichtenthaler GL, Ladutko EI, Nowicky JW: **Influence of Ukrain on the nuclear thyroid hormone receptors after short-term gamma-irradiation.** *Drugs Exp Clin Res* 2000, **26**:307-10.
82. Luksa-Lichtenthaler GL, Ladutko EI, Nowicky JW: **Radiomodification effects of Ukrain, a cytostatic and immunomodulating drug, on intracellular glucocorticoid reception during short-term gamma-irradiation.** *Drugs Exp Clin Res* 2000, **26**:311-5.
83. Jablonski M, Korczak W, Gorzelak M, Jagiell-Wojtowicz E: **Intermittent three-month treatment with Ukrain in intact and ovariectomized rats. Part III: Effect on the nativ electron paramagnetic resonance signal intensity of the femur.** *Drugs Exp Clin Res* 2000, **26**:333-6.
84. Stabuc B, Benedicic D: **Ukrain with chemotherapy in malignant melanoma (case report).** *Drugs Exp Clin Res* 1996, **22**:231-3.
85. Hamler F, Hiesmayr W, Korsh O, Melnyk A: **Ukrain monotherapy in malignant melanoma (case report).** *Drugs Exp Clin Res* 1996, **22**:235-7.
86. Kotsay B, Lisnyak O, Myndiuk O, Romanysh-hyn J, Fabri O: **Ukrain treatment of rhabdomyosarcoma (case report).** *Drugs Exp Clin Res* 1996, **22**:239-41.
87. Kadan P, Korsh OB, Melnyk A: **Ukrain therapy of recurrent breast cancer with lung metastases (case report).** *Drugs Exp Clin Res* 1996, **22**:243-5.
88. Schramm E, Nowicky JW, Godysch Y: **Biophysiological effects of Ukrain therapy in a patient with breast cancer (case report).** *Drugs Exp Clin Res* 1996, **22**:247-54.
89. Kroiss T, Melnyk A, Korsh OB: **Ukrain treatment in carcinoma of the cervix (case report).** *Drugs Exp Clin Res* 1996, **22**:255-7.
90. Lohninger A, Korsh OB, Melnyk A: **Combined therapy with Ukrain and chemotherapy in ovarian cancer (case report).** *Drugs Exp Clin Res* 1996, **22**:259-62.
91. Sakalo VS, Korsh OB, Melnyk A: **Ukrain treatment in a patient with non-seminomatous germ-cell tumour of testis (case report).** *Drugs Exp Clin Res* 1996, **22**:263-5.
92. Vyas JJ, Jain VK: **Ukrain treatment in carcinoma of the oesophagus (case report).** *Drugs Exp Clin Res* 1996, **22**:267-9.
93. Kadan P, Korsh OB, Hiesmayr W: **Ukrain in the treatment of urethral recurrent carcinoma (case report).** *Drugs Exp Clin Res* 1996, **22**:271-3.
94. Steinacker J, Kroiss T, Korsh OB, Melnyk A: **Ukrain therapy in a frontal anaplastic grade III astrocytoma (case report).** *Drugs Exp Clin Res* 1996, **22**:275-7.
95. Steinacker J, Korsh OB, Melnyk A: **Ukrain therapy of a recurrent astrocytoma of the optic nerve (case report).** *Drugs Exp Clin Res* 1996, **22**:279-81.
96. Voltchek IV, Liepins A, Nowicky JW, Brzosko WJ: **Potential therapeutic efficacy of Ukrain (NSC 631570) in AIDS patients with Kaposi's sarcoma.** *Drugs Exp Clin Res* 1996, **22**:283-6.
97. Aschhoff B: **Ukrain treatment in a patient with stage IV neuroblastoma. A case report.** *Drugs Exp Clin Res* 1998, **24**:243-5.
98. Nowicky JW, Staniszewski A, Zbroja-Sontag W, Slesak B, Nowicky W, Hiesmayr W: **Evaluation of thiophosphoric acid alkaloid derivatives from Chelidonium majus L. ("Ukrain") as an immunostimulant in patients with various carcinomas.** *Drugs Exp Clin Res* 1991, **17**:139-43.
99. Danysz A, Kokoschinegg M, Hamler F: **Clinical studies of Ukrain in healthy volunteers (phase I).** *Drugs Exp Clin Res* 1992, **18**:39-43.
100. Musianowycz J, Judmajer F, Manfreda D, Spangler P, Albrecht H, Hoffmann J, et al.: **Clinical studies of Ukrain in terminal cancer patients (phase II).** *Drugs Exp Clin Res* 1992, **18**:45-50.
101. Nowicky JW, Manolakis G, Meijer D, Vatanasapt V, Brzosko WJ: **Ukrain both as an anti cancer and immunoregulatory agent.** *Drugs Exp Clin Res* 1992, **18**:51-4.
102. Danilos J, Zbroja-Sontag W, Baran E, Kurylcio L, Kondratowicz L, Jusiak L: **Preliminary studies on the effect of Ukrain (Tris(2-[(5bS-(5ba, 6b, 12ba)]-5b, 6, 7, 12b, 13, 14-hexahydro-13-methyl[1, 3] benzodioxolo [5, 6-v]-1-3-dioxolo [4, 5-i] phenanthridinium-6-ol]-Ethaneaminy]) Phosphinesulfide.6HCl) on the immunological response in patients with malignant tumours.** *Drugs Exp Clin Res* 1992, **18**:55-62.
103. Pengsaa P, Wongpratoom W, Vatanasapt V, Udomthavornasuk B, Mairieng E, Tangvorapongchai V, et al.: **The effects of thiophosphoric acid (Ukrain) on cervical cancer, stage IB bulky.** *Drugs Exp Clin Res* 1992, **18**:69-72.
104. Lohninger A, Hamler F: **Chelidonium majus L. (Ukrain) in the treatment of cancer patients.** *Drugs Exp Clin Res* 1992, **18**:73-7.
105. Brzosko WJ, Uglyanitsa KN, Fomin KA, Nowicky JW: **Influence of Ukrain on breast cancer.** *Drugs Exp Clin Res* 1996, **22**:127-33.
106. Zemskov SV, Iaremchuk OI, Susak IaM, Deneka IaR, Kravchenko OV, Iatsyk IM: **The initial experience of use of the preparation Ukrain in treating cancer patients in Ukraine.** *Lik Sprava* 1996, **Jan-Feb**:158-61.
107. Nefyodov LI, Uglyanitsa KN, Smirnov VY, Karavay AV, Brzosko WJ: **Comparative evaluation of blood plasma and tumor tissue amino acid pool in radiation or neoadjuvant preoperative therapies of breast cancer with the antitumour drug Ukrain.** *Drugs Exp Clin Res* 2000, **26**:231-7.
108. Uglyanitsa KN, Nefyodov LI, Karayedova LM, Nowicky JW, Brzosko WJ: **Clinical aspects of cancer treatment and new biochemical mechanisms of the drug Ukrain.** *Drugs Exp Clin Res* 2000, **26**:239-47.
109. Nefyodov LI, Uglyanitsa KN, Smirnov VY, Doroshenko YM, Fomin KA, Nowicky JW, et al.: **Amino acids and their derivatives in tumour tissue from patients with breast cancer treated with Ukrain. Part VI.** *Drugs Exp Clin Res* 1996, **22**:159-61.
110. Nefyodov LI, Uglyanitsa KN, Smirnov VY, Doroshenko YM, Fomin KA, Nowicky JW, et al.: **Amino acids and their derivatives in blood plasma of patients with breast cancer treated with Ukrain. Part V.** *Drugs Exp Clin Res* 1996, **22**:155-7.
111. Uglyanitsa KN, Maciuk JR, Fomin KA, Nefyodov LI, Kravchuk RI, Vinogradova LM, et al.: **Influence of Ukrain on patients with surgically treated breast cancer. Part IV.** *Drugs Exp Clin Res* 1996, **22**:147-53.
112. Fomin KA, Uglyanitsa KN, Nefyodov LI, Djurd TI, Nowicky JW, Brzosko WJ, et al.: **Influence of Ukrain on patients with surgically treated breast cancer. Part III. The immune system.** *Drugs Exp Clin Res* 1996, **22**:143-5.
113. Uglyanitsa KN, Fomin KA, Nefyodov LI, Vilkiewicz TW, Nowicky JW, Brzosko WJ, et al.: **Influence of Ukrain on patients with surgically treated breast cancer. Part II. Hormonal profile.** *Drugs Exp Clin Res* 1996, **22**:139-43.
114. Uglyanitsa KN, Fomin KA, Nefyodov LI, Nowicky JW, Brzosko WJ, Jankowski A: **Influence of Ukrain on patients with surgically treated breast cancer. Part I. Clinical and laboratory parameters.** *Drugs Exp Clin Res* 1996, **22**:135-8.
115. Nefyodov LI, Uglyanitsa KN, Nechiporenko NA, Smirnov VY, Brzosko WJ, Karavay NL: **New biochemical mechanisms of the anticancer effect of Ukrain in the treatment of cancer of the urinary bladder.** *Drugs Exp Clin Res* 2000, **26**:195-9.
116. Uglyanitsa KN, Nechiporenko NA, Nefyodov LI, Brzosko WJ: **Ukrain therapy of stage TINOMO bladder cancer patients.** *Drugs Exp Clin Res* 1998, **24**:227-30.

117. Uglyanitsa KN, Fomin KA, Nefyodov LI, Nowicky JW, Brzosko WJ, Jankowski A: **Influence of Ukrain on patients with surgically treated breast cancer (introductory remarks).** *Drugs Exp Clin Res* 1996, **22**:123-5.
118. Uglyanitsa KN, Nefyodov LI, Doroshenko YM, Brzosko WJ: **Comparison of the efficacy of different doses of Ukrain in the combined treatment of breast cancer.** *Drugs Exp Clin Res* 2000, **26**:201-21.
119. Jadad AR, Moore A, Carroll D, Jenkinson C, Reynolds DJM, Gavaghan DJ, et al.: **Assessing the quality of reports of randomized clinical trials: Is blinding necessary.** *Controlled Clin Trials* 1996, **17**:1-12.
120. Susak YM, Zemskov SV, Yaremchuk OY, Kravchenko OV, Yatsyk IM, Korsh OB: **Comparison of chemotherapy and X-ray therapy with Ukrain monotherapy for colorectal cancer.** *Drugs Exp Clin Res* 1996, **22**:115-22.
121. Bondar GV, Borota AV, Yakovets YI, Zolotukhin SE: **Comparative evaluation of the complex treatment of rectal cancer patients (chemotherapy and X-ray therapy, Ukrain monotherapy).** *Drugs Exp Clin Res* 1998, **24**:221-6.
122. Zemskov VS, Prokopchuk OL, Susak YM, Zemskov SV, Hodysh YY, Zemskova MV: **Ukrain (NSC-631570) in the treatment of pancreas cancer.** *Drugs Exp Clin Res* 2000, **26**:179-90.
123. Uglyanitsa KN, Nefyodov LI, Brzosko WJ: **Comparative evaluation of the efficiency of various Ukrain doses in the combined treatment of breast cancer. Report I. Clinical aspects of Ukrain application.** *Drugs Exp Clin Res* 2000, **26**:223-30.
124. Zemskov SV, Prokopchuk O, Susak Y, Zemskov S, Tkachenko O, Hodysh Y, et al.: **Efficacy of Ukrain in the treatment of pancreatic cancer.** *Langenbecks Arch Surg* 2002, **387**:84-9.
125. Gansauge F, Ramadani M, Pressmar J, Gansauge S, Muehling B, Stecker K, et al.: **NSC-631570 (Ukrain) in the palliative treatment of pancreatic cancer. Results of a phase II trial.** *Langenbecks Arch Surg* 2002, **386**:570-4.
126. Susak YM, Yaremchuk OY, Zemskov VS, Kravchenko OB, Liepins A, Yatsyk IM, et al.: **Randomised clinical study of Ukrain on colorectal cancer.** *Eur J Cancer* 1995, **31**:S153. Abstract 733.
127. Anon: **Phase II Studie zur Behandlung des fortgeschrittenen, inoperablen Pankreaskarzinoms mit Ukrain.** *Der Arzneimittelbrief* 2002, **36**:39.
128. Jellin JM, Gregory P, Batz F, Hitchens K, et al.: **Pharmacist's Letter/Prescriber's Letter Natural Medicines Comprehensive Database.** 3rd edition. Stockton, CA: Therapeutic Research Faculty; 2000.
129. Benninger J, Schneider HT, Schuppan D, Kirchner T, Hahn EG: **Acute hepatitis induced by Greater Celandine (Chelidonium majus).** *Gastroenterol* 1999, **117**:1234-7.
130. Jagiello-Wojtowicz E, Kleinrok Z, Urbanska EM: **Ukrain (NSC-631570) in experimental and clinical studies: a review.** *Drugs Exp Clin Res* 1998, **24**:213-9.
131. Bone K: **Adverse reaction reports: hepatitis induced by greater celandine.** *Phytother* 2000, **5**:11-6.
132. Crijns APG, De Smet PAGM, van den Heuvel M, Schot BW, Haagsma EB: **Acute hepatitis after use of herbal preparation with greater celandine.** *Ned Tijdschr Geneesk* 2002, **146**:124-8.
133. Hopf G: **Ukrain® – Fortschritt oder Rückschritt in der medikamentösen Therapie onkologischer Erkrankungen?** *Deutsche Zeitschrift für Onkologie* 2002, **34**:31-6.

### Pre-publication history

The pre-publication history for this paper can be accessed here:

<http://www.biomedcentral.com/1471-2407/5/69/prepub>

Publish with **BioMed Central** and every scientist can read your work free of charge


"BioMed Central will be the most significant development for disseminating the results of biomedical research in our lifetime."

Sir Paul Nurse, Cancer Research UK

Your research papers will be:

- available free of charge to the entire biomedical community
- peer reviewed and published immediately upon acceptance
- cited in PubMed and archived on PubMed Central
- yours — you keep the copyright

Submit your manuscript here:  
[http://www.biomedcentral.com/info/publishing\\_adv.asp](http://www.biomedcentral.com/info/publishing_adv.asp)



МІНІСТЕРСТВО ОХОРОНИ ЗДОРОВ'Я УКРАЇНИ  
ДЕРЖАВНИЙ ФАРМАКОЛОГІЧНИЙ ЦЕНТР  
м. Київ

## РЕЄСТРАЦІЙНЕ ПОСВІДЧЕННЯ НА ЛІКАРСЬКИЙ ЗАСІБ

№ UA/9110/01/01

Рішення про державну *перереєстрацію* лікарського засобу  
затверджене наказом МОЗ України від 11.11.2008 № 648

Згідно зі ст.9 Закону України "Про лікарські засоби" та постановою  
Кабінету Міністрів України від 26.05.2005 № 376 "Про затвердження  
Порядку державної реєстрації (перереєстрації) лікарських засобів і  
розмірів збору за їх державну реєстрацію (перереєстрацію)" лікарський  
засіб

УКРАЇН,

розчин для ін'єкцій, 5 мг/5 мл

*перереєстрований* в Україні терміном на 5 років

Заявник:

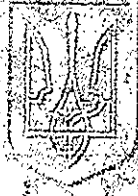*Новіцкі Фарма, Австрія*  
*Margaretenstrasse 7, A-1040 Відень, Австрія*  
*Nowicky Pharma, Austria*  
*Margaretenstr.7, A-1040, Vienna, Austria*

Реєстраційне посвідчення діє на всій території України до 11.11.2013

Реєстраційне посвідчення видане 12.11.2008

17005

РП 16058



**МІНІСТЕРСТВО ОХОРОНИ ЗДОРОВ'Я УКРАЇНИ**  
**РЕЄСТРАЦІЙНЕ ПОСВІДЧЕННЯ**

№ 3641

від 02.09.03

Це посвідчення видане:

"Новіцкі Фарма", Австрія / "Nowicky-Pharma", Austria

в тому, що відповідно до Порядку державної реєстрації (перереєстрації) лікарського засобу, затвердженого Постановою Кабінету Міністрів України від 13.09.2000 р. № 1422, лікарський засіб під назвою:

**УКРАЇН**

складу:

Діючі речовини:

5 мл розчину містять: сполуки алкалоїдів чистотилу великого з тіофосфорною кислотою 5 мг

6267  
 АД

зарєєстрований в Україні у вигляді лікарської форми:

розчин для ін'єкцій по 5 мл (5 мг) в ампулах № 1

Посвідчення видане: 2 вересня 2003 р.

Посвідчення дійсне до: 2 вересня 2008 р.



Міністр

А.В. Підасю



МІНІСТЕРСТВО ОХОРОНИ ЗДОРОВ'Я УКРАЇНИ  
MINISTRY OF HEALTH OF UKRAINE

РЕЄСТРАЦІЙНЕ  
ПОСВІДЧЕННЯ

REGISTRATION  
CERTIFICATE

Ministry of Health of Ukraine  
Bureau for Pharmaceuticals Registration

Registration Certificate  
# 3641

*This certificate is issued to the firm*  
"Nowicky-Pharma", Austria

*ascertaining that in compliance with the regulation set by Ministry of Health of*  
*Ukraine, the preparation called*

UKRAIN

*is registered in Ukraine as a therapeutic form*  
solution for injections 5 ml (5 mg) in ampules N 1

*The certificate is not a commitment for purchasing this preparation.*

*The certificate is issued on:*


"15" October 1998

*The certificate is valid until:*

"15" October 2003

Chairman

Bureau for Pharmaceuticals Registration



*Andriy M. Serdiuk*

# Міністерство охорони здоров'я України

Бюро реєстрації лікарських засобів

## Реєстраційне посвідчення

### № 3641

Це посвідчення видане фірмі  
"Новіцький-Фарма", Австрія

в тому, що відповідно до порядку, встановленого Міністерством охорони  
здоров'я України, препарат під назвою

**УКРАЇН**

зарєєстрований в Україні у вигляді лікувальної форми:  
розчин для ін'єкцій по 5 мл (5 мг) в ампулах № 1

Посвідчення не є зобов'язанням щодо закупівлі цього препарату.

Посвідчення видане  
Посвідчення дійсне до

"15" жовтня 1998 р.

"15" жовтня 2003 р.

Голова

Бюро реєстрації лікарських засобів



*А.М. Сердюк*  
А.М. Сердюк





Office of Orphan Products Development (HF-35)  
Food and Drug Administration  
5600 Fishers Lane  
Rockville, MD 20857

August 20, 2003

Bohdan Hugel  
US Agent for Now Pharm AG  
3250 Glase Road  
Danielsville, PA 18038

Re: Designation Request # 03-1693

Dear Mr. Hugel:

Reference is made to your request, submitted on behalf of Now Pharm AG, for orphan-drug designation dated February 27, 2003, of 5,5',5"-[phosphinothioylidene-tris(imino-2,1-ethanediyl)] tris[5-methylchelidoninium] trihydroxide hexahydrochloride for the treatment of pancreatic cancer. Reference is also made to our acknowledgement letter dated April 8, 2003.


Pursuant to section 526 of the Federal Food, Drug, and Cosmetic Act (21 U.S.C. § 360bb), your request for orphan drug designation of 5,5',5"-[phosphinothioylidene-tris(imino-2,1-ethanediyl)] tris[5-methylchelidoninium] trihydroxide hexahydrochloride for the treatment of pancreatic cancer is granted.

Please note that it is the active moiety of the drug and not its formulation that is designated. Please also note that if the above product receives marketing approval for an indication broader than what is designated, it may not be entitled to exclusive marketing rights under section 527 (21 U.S.C. § 360cc). Therefore, prior to final marketing approval, we request that you compare the product's designated orphan indication with the proposed marketing indication, and submit additional information to amend the orphan-drug designation if warranted.

Please submit to the Office of Orphan Products Development a brief progress report of drug development within 14 months after this date and annually thereafter until marketing approval (*see* 21 C.F.R. § 316.30). Finally, please notify this Office within 30 days of a marketing application submission for the product's designated use.

If you need further assistance in the clinical development of your product, please feel free to contact John J. McCormick, MD, at (301) 827-3666. Please refer to this letter as official notification and congratulations on obtaining your orphan-drug designation.

Sincerely yours,

A handwritten signature in cursive script, appearing to read "Marlene E. Haffner".

Marlene E. Haffner, MD, MPH  
Rear Admiral, United States Public Health Service  
Director, Office of Orphan Products Development



**Australian Government**  
**Department of Health and Ageing**  
**Therapeutic Goods Administration**

File: 2004/009839

Mrs Aleksandra Harasemcuk  
40 Harcourt Avenue  
Kealba VIC 3021

Dear Mrs Harasemcuk

**Re: NSC-631570 (Ukraine) – Orphan Drug Application**

I refer to your letter of 30 April 2004 seeking orphan drug designation for NSC-631570 (Ukraine), for the treatment of pancreatic cancer.

Consideration of your application (**Application No. 03-1456-4**) has been completed.

I have decided, pursuant to subregulation 16J(2) of the *Therapeutic Goods Regulation: 1990* to designate NSC-631570 (Ukraine) as an orphan drug. The indication is for the treatment of pancreatic cancer.

The Therapeutic Goods Administration (TGA) would appreciate advice on when you plan to submit an application to register the designated medicine. **It is strongly recommended that you meet with staff of the TGA prior to submitting such an application, to discuss data requirements.** If the indication in your application to register the medicine differs from that in your application for orphan drug designation, additional data may be required to demonstrate that orphan designation still applies.

Yours sincerely

A handwritten signature in black ink, appearing to read 'L. Hunt', written over a horizontal line.

Dr Leonie Hunt  
Director  
Drug Safety and Evaluation Branch  
Delegate of the Secretary

Dated this 8th day of June 2004